

TESIS DOCTORAL

**CARACTERIZACIÓN CLÍNICA Y
ELECTROFISIOLÓGICA DE LAS ALTERACIONES
RECÍPROCAS DEL ELECTROCARDIOGRAMA EN
EL INFARTO AGUDO DE MIOCARDIO**

Doctorando

Francisco Javier Noriega Sanz

Director

Dr. Juan María Cinca Cuscullola

Departamento de Medicina

Universitat Autònoma de Barcelona

2015



TESIS DOCTORAL

**CARACTERIZACIÓN CLÍNICA Y
ELECTROFISIOLÓGICA DE LAS ALTERACIONES
RECÍPROCAS DEL ELECTROCARDIOGRAMA EN
EL INFARTO AGUDO DE MIOCARDIO**

Departamento de Medicina

Universitat Autònoma de Barcelona

2015

Doctorando

Francisco Javier Noriega Sanz

Director

Dr. Juan María Cinca Cuscollola

AGRADECIMIENTOS

Al Dr. Juan Cinca, director y verdadero artífice de esta tesis, por permitirme descubrir el mundo de la investigación básica y disfrutar de él. Gracias por todas las horas e ilusión invertidas en este proyecto.

Al Dr. Xavier Borrás, por inculcarme la tenacidad y metodología en el trabajo.

Al Dr. Christian Muñoz, por sus lecciones estadísticas y sus sabios consejos.

Al equipo de Cardiología Experimental, por hacer más fácil el trabajo. A Esther y Dabit, sin cuya inestimable colaboración no habría podido desarrollar este proyecto.

A Jesús y David, mis compañeros de residencia, por su apoyo incondicional durante todos estos años.

A mis residentes mayores y pequeños, por todo lo que he aprendido de ellos.

A Miquel y Eduard, por su ayuda desinteresada en este proyecto.

A todos los profesionales que forman parte del servicio de Cardiología, gracias a los cuales he podido completar mi formación como cardiólogo.

A mis padres, Javier y Teodora, por la educación y el cariño recibidos. A mi hermana, Elena, por estar siempre ahí.

A Ana, por formar parte de mi vida. Por tenerte siempre que te necesito. Por la paciencia y los ánimos recibidos durante la elaboración de esta tesis.

ÍNDICE

RESUMEN	13
ABREVIATURAS.....	17
INTRODUCCIÓN	19
1. Cardiopatía isquémica.....	19
1.1. Epidemiología	19
1.2. Fisiopatología.....	21
2. Electrocardiograma.....	29
2.1. Conceptos básicos.....	29
2.2. El electrocardiograma en la isquemia miocárdica.....	34
2.3. Patrones electrocardiográficos en la isquemia miocárdica aguda: correlación eléctrica y anatómica.....	38
HIPÓTESIS Y OBJETIVOS.....	45
1. Hipótesis.....	45
2. Objetivos.....	45
2.1. Objetivo general.....	45
2.2. Objetivos específicos	46

RESULTADOS.....	49
1. Artículo 1: Mechanism and diagnostic potential of reciprocal ECG changes induced by acute coronary artery occlusion in pigs.....	49
2. Artículo 2: Influence of the extent of coronary artherosclerotic disease on ST-segment changes induced by ST elevation myocardial infarction.....	61
3. Artículo 3: ST-segment deviation behaviour during acute myocardial ischemia in opposite ventricular regions: Observations in the intact and perfused heart.....	73
DISCUSIÓN	85
1. Génesis y comportamiento de los cambios recíprocos del segmento ST y del complejo QRS.....	85
2. Correlación entre los patrones del segmento ST y la angiografía coronaria.....	87
3. Comportamiento del segmento ST en la enfermedad coronaria multivaso.....	89
4. Isquemia miocárdica simultánea en dos regiones opuestas.....	90
CONCLUSIONES.....	93
BIBLIOGRAFÍA	95

RESUMEN

La isquemia miocárdica transmural, producida por oclusión coronaria aguda, genera unos cambios en la actividad eléctrica del corazón, como consecuencia de las alteraciones metabólicas que suceden en los miocardiocitos por la falta de flujo coronario. Estos cambios se manifiestan en el ECG como elevación del segmento ST en las derivaciones enfrentadas al área isquémica, lo que permite realizar una aproximación de la localización de la oclusión arterial coronaria. Adicionalmente puede producirse descenso del segmento ST en las derivaciones alejadas del área isquémica, lo que se conoce como cambios recíprocos. El mecanismo electrofisiológico y las implicaciones clínicas de dichos cambios recíprocos no son bien conocidos.

Esta tesis consta de tres trabajos en los que se realiza un análisis traslacional de las alteraciones recíprocas del ECG en el infarto agudo de miocardio producido por oclusión arterial coronaria. La parte experimental se desarrolla en un modelo porcino de isquemia miocárdica. La parte clínica analiza un grupo de pacientes con infarto agudo de miocardio sometidos a angioplastia primaria. Los resultados de estos trabajos permiten realizar una caracterización electrofisiológica de los cambios recíprocos del segmento ST, al observarse éstos en ausencia de isquemia subendocárdica añadida a distancia, explicándose su presencia por las características de los sistemas de registro del ECG. Asimismo, la integración de los cambios recíprocos junto con las alteraciones directas del segmento ST permite localizar de una manera más

precisa la oclusión arterial coronaria, pudiendo validarse los patrones del ECG también en presencia de enfermedad arterial coronaria multivaso.

SUMMARY

Transmural myocardial ischemia induced by acute coronary artery occlusion induces electric and metabolic changes in myocardial cells caused by the interruption of coronary blood flow. These changes are recorded in the conventional ECG as ST segment elevation in leads directly related to the ischemic region, and they allow to predict the location of the coronary artery occlusion. In addition, reciprocal ST segment depression could be present in ECG leads overlying distant non ischemic areas. The electrophysiologic mechanism and clinical implications of these reciprocal changes are not well known.

This thesis consist of three translational studies which analyze the reciprocal ECG changes in the onset of an acute myocardial infarction due to a coronary artery occlusion. The experimental studies are developed in a porcine model of myocardial ischemia. The clinical study included patients with an acute myocardial infarction submitted to primary coronary reperfusion. Results from these studies allow to get insight into the electrophysiologic characterization of reciprocal ST segment changes, which are not caused by added subendocardial ischemia at a distance, but related to the ECG lead system design. Moreover, the combined analyses of direct and reciprocal ST segment changes predicts more accurately the location of the coronary artery occlusion,

being the ECG patterns also valid in patients with multivessel coronary artery disease.

ABREVIATURAS

ATP: Adenosin trifosfato

AV: Aurículo-ventricular

ECG: Electrocardiograma

I_{Ca-L} : Corriente de calcio tipo L

I_{K1} : Corriente de potasio inward rectifier

I_{K-ATP} : Corriente de potasio dependiente de ATP

I_{Kr} : Corriente de potasio rapid delayed rectifier

I_{Ks} : Corriente de potasio slow delayed rectifier

I_{Na} : Corriente de sodio voltaje dependiente

SCACEST: Síndrome coronario agudo con elevación del segmento ST

SCASEST: Síndrome coronario agudo sin elevación del segmento ST

V_m : potencial de membrana

INTRODUCCIÓN

1. Cardiopatía isquémica

1.1. Epidemiología

Las enfermedades cardiovasculares constituyen la principal causa de muerte en los países desarrollados, siendo responsables de una tercera parte de las muertes a nivel mundial, cifra que se eleva hasta un 46% en Europa (Figura 1) (1-2). Dentro de las enfermedades cardiovasculares, la cardiopatía isquémica es la entidad con mayor mortalidad, tanto a nivel global como en países desarrollados. Según la Organización Mundial de la Salud, la mortalidad global atribuible a cardiopatía isquémica en 2011 fue cercana a los 7 millones de personas, lo que supuso un incremento de 1.1 millones de defunciones respecto al año 2000 (3). Una de cada seis muertes en Estados Unidos (1) y una de cada cinco en Europa (2) se deben a cardiopatía isquémica. Para el año 2020, se prevé que el número total de muertes por enfermedad arterial coronaria se eleve a 11.1 millones (3).

En España las enfermedades cardiovasculares constituyen también la primera causa de hospitalización y muerte (4). Su incidencia y prevalencia aumentan con la edad, por lo que se objetiva un incremento en la mortalidad asociado al envejecimiento progresivo de la población (5).

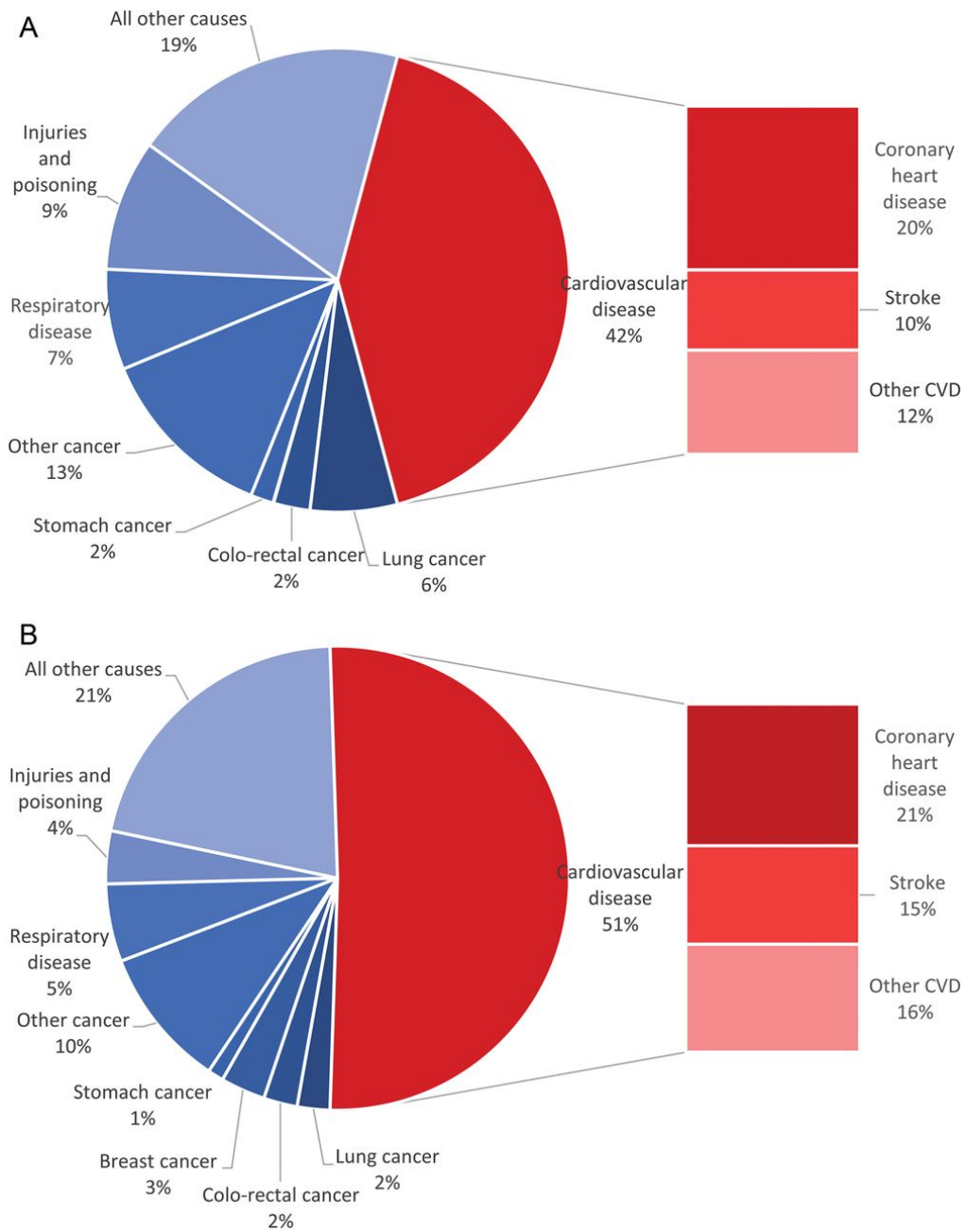


Figura 1. Proporción de muertes debidas a las principales causas de mortalidad en Europa, en hombres (A) y mujeres (B). Imagen tomada de Nichols et al (2).

1.2. Fisiopatología

1.2.1. Circulación coronaria

El flujo sanguíneo coronario presenta importantes variaciones a lo largo del ciclo cardiaco, objetivándose un desfase entre el flujo de entrada en las arterias coronarias y el de salida por las venas. Durante la sístole, la contracción cardíaca aumenta la presión tisular, redistribuyéndose la perfusión desde la capa subendocárdica a la subepicárdica. De forma simultánea, se reduce el diámetro de los vasos de la microcirculación intramiocárdica y se incrementa el flujo venoso coronario, que alcanza su máximo en esta fase. En la diástole, el flujo arterial coronario aumenta creando un gradiente transmural que favorece la perfusión de los vasos subendocárdicos, mientras que el flujo venoso coronario decae.

La resistencia al flujo coronario viene determinada por tres componentes: a) la presión en las arterias epicárdicas o de conducción, b) la resistencia de la microcirculación (reserva de flujo coronario), y c) la resistencia extravascular compresiva (dependiente de la contracción del corazón y la presión sistólica en el ventrículo izquierdo). En circunstancias normales, la presión en las arterias epicárdicas se mantiene constante gracias a un mecanismo de autorregulación, lo que indica que la resistencia de los vasos de conducción es insignificante.

Sin embargo, cuando se produce un estrechamiento arterial epicárdico superior al 50%, la resistencia arterial de los vasos de conducción comienza a contribuir de manera creciente a la resistencia coronaria total. Si la estenosis sigue aumentando, los incrementos en la resistencia se acompañan de una mayor diferencia de presión a través de la estenosis, reduciéndose la presión coronaria distal a la estenosis, que es el principal determinante de la perfusión de la microcirculación. Las estenosis superiores al 70% comprometen la reserva de flujo coronario, y cuando la estenosis es crítica (>90%) puede verse afectado el flujo en reposo (6).

1.2.2. Alteraciones metabólicas y celulares

La interrupción brusca de la perfusión miocárdica tras una oclusión coronaria conlleva una serie de cambios fisiológicos y metabólicos que aparecen a los pocos segundos de haber cesado el flujo coronario. El metabolismo aerobio deja paso a la glucólisis anaerobia, produciéndose una reducción progresiva de las concentraciones hícticas de adenosin trifosfato (ATP), una acumulación de catabolitos y un incremento en la producción de lactato. Si la isquemia se mantiene, se desarrolla una acidosis y el potasio comienza a salir hacia el espacio extracelular. Más tarde, las concentraciones de ATP caen por debajo de las requeridas para mantener la función de la membrana, con lo que se inicia la muerte del miocardiocito (7).

Durante la isquemia miocárdica se generan una serie de cambios eléctricos a nivel celular, en respuesta a la hipoxia, la acidosis y la salida de potasio a nivel extracelular. Estos cambios producen una reducción en el potencial de reposo transmembrana, una disminución de la excitabilidad, y el acortamiento en la duración del potencial de acción (8).

El mantenimiento del potencial de reposo transmembrana depende en gran medida de la corriente que se genera a través de los canales de potasio inward rectifier (I_{K1}), que originan una salida de potasio a nivel extracelular. En situación de isquemia miocárdica, por efecto de la hipoxia celular, se produce un incremento en la conductancia del potasio, lo que conlleva una reducción del potencial de reposo, despolarizándose la membrana (8-9).

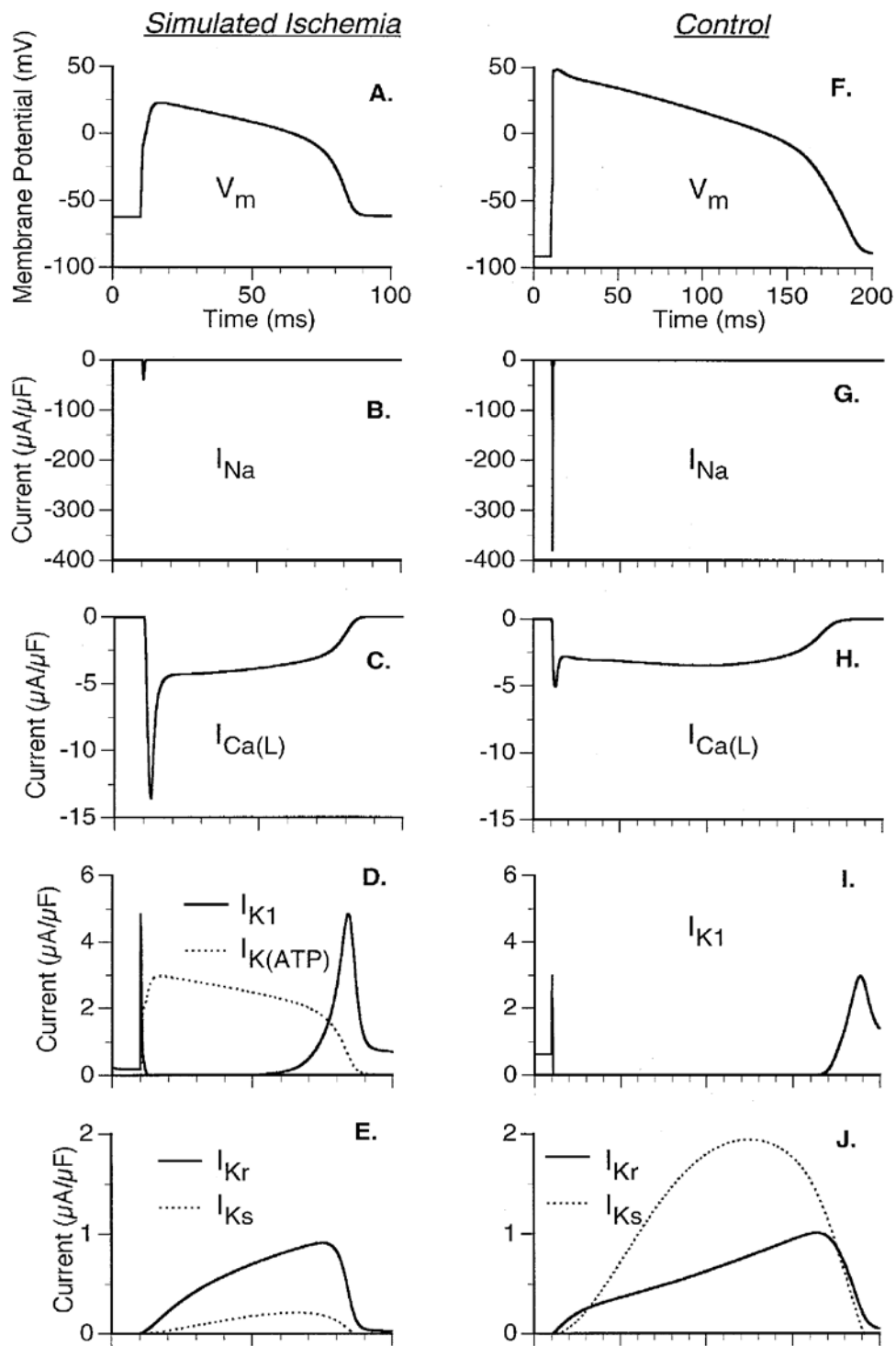


Figura 2. Potencial de acción y principales corrientes iónicas del potencial de membrana en situaciones basal y de isquemia miocárdica. I_{Ca-L} : corriente de calcio tipo L, I_{K1} : corriente de potasio inward rectifier, I_{K-ATP} : corriente de potasio dependiente de ATP, I_{Kr} : corriente de potasio rapid delayed rectifier, I_{Ks} : corriente de potasio slow delayed rectifier, I_{Na} : corriente de sodio voltaje dependiente, V_m : potencial de membrana. Imagen tomada de Shaw et al (8).

La excitabilidad de la célula depende del nivel del potencial de reposo transmembrana y de la fase de despolarización rápida (fase 0), originada en condiciones normales por la apertura de los canales de sodio voltaje dependientes (I_{Na}). Durante la isquemia miocárdica, el aumento del potasio extracelular induce una despolarización del potencial de reposo y una reducción en la disponibilidad de los canales I_{Na} . La reducción de la corriente de sodio activa los canales de calcio tipo L (I_{Ca-L}), responsables de la despolarización rápida de la membrana en situación de isquemia. Sin embargo, por efecto de la acidosis, tanto la conductancia del sodio como la del calcio se ven disminuidas, con lo que la despolarización rápida se compromete, y la excitabilidad celular se ve reducida (Figura 2) (8).

La duración del potencial de acción depende fundamentalmente de la fase 2 o plateau. En condiciones de isquemia e hipoxia se produce un consumo de los niveles citosólicos de ATP, activándose los canales de potasio dependientes de ATP (I_{K-ATP}). Esta activación conlleva una mayor salida de potasio durante la fase 2, modificándose la forma de dicha fase y produciéndose una repolarización precoz de la membrana celular, con el consiguiente acortamiento en la duración del potencial de acción (Figura 2) (8, 10).

1.2.3. Formas fisiopatológicas

La cardiopatía isquémica engloba diferentes entidades clínicas, desde la angina crónica estable hasta los síndromes coronarios agudos, tales como el infarto agudo de miocardio y la angina inestable.

La angina crónica estable se debe en la mayoría de los casos a una obstrucción de las arterias coronarias provocada por placas de ateroma. Cuando la obstrucción coronaria es significativa, se puede producir isquemia por un desequilibrio entre las necesidades y el aporte de oxígeno al miocardio (11). El aumento en las necesidades de oxígeno está relacionado con la liberación de noradrenalina en las terminaciones nerviosas adrenérgicas del corazón y del lecho vascular, en respuesta fisiológica al ejercicio o al estrés emocional o mental. El aporte de oxígeno puede disminuir de forma transitoria si se produce una vasoconstricción coronaria, favorecida por la presencia de estenosis coronarias y lesiones endoteliales ateromatosas, que generan una respuesta vasoconstrictora anormal al ejercicio y a otros estímulos. Se genera así un umbral variable de isquemia miocárdica, a partir del cual aparecen las manifestaciones clínicas de la angina. La restauración del equilibrio entre las necesidades y el aporte de oxígeno (ya sea por el cese de la actividad física o emocional que desencadenó el aumento de las necesidades, o por incremento del aporte de oxígeno mediante vasodilatación coronaria fisiológica o farmacológica), conlleva la

corrección de la isquemia miocárdica y la desaparición de la clínica anginosa.

Los síndromes coronarios agudos producen también isquemia miocárdica por reducción en el aporte de oxígeno, pero ésta aparece en reposo, y el mecanismo fisiopatológico es, en la mayoría de los casos, la inestabilización o rotura de una placa ateromatosa. Existen diversos factores favorecedores de la rotura de una placa aterosclerótica, algunos de ellos son intrínsecos a las características de la placa, que la hacen más vulnerable (formación de metaloproteasas, activación de mastocitos y macrófagos), mientras que otros se deben al estrés provocado por la presión intraluminal, el tono vasomotor coronario, la taquicardia o la rotura de los vasos nutricios (12). La rotura de la placa conlleva la exposición de la matriz subendotelial al torrente sanguíneo, lo que facilita la adherencia plaquetaria a través de la unión de diversas glicoproteínas al factor de von Willebrand y al colágeno. Seguidamente se produce la activación plaquetaria, liberándose sustancias quimiotácticas (tromboxano A₂ y serotonina), y la agregación plaquetaria, mediada por la unión de la glicoproteína IIb/IIIa al fibrinógeno. Al mismo tiempo que se genera el coágulo plaquetario, se activa también la cascada de la coagulación, que en último término conduce a la formación de trombina, la cual favorece la conversión de fibrinógeno en fibrina, estimula potentemente la agregación plaquetaria y estabiliza el coágulo de fibrina (13). El trombo resultante interrumpe el flujo sanguíneo, produciéndose

un desequilibrio entre el suministro y la demanda de oxígeno. Si el trombo es oclusivo, se genera isquemia miocárdica transmural, registrándose en el electrocardiograma (ECG) elevación del segmento ST. Si el trombo no es oclusivo, la isquemia no afecta a todo el espesor del miocardio, sino que se limita a la zona subendocárdica, lo que puede conllevar en el ECG un descenso del segmento ST o alteraciones en la onda T. Se separan así los síndromes coronarios agudos en los que presentan elevación del segmento ST (SCACEST), que se benefician de una reperfusión inmediata (mecánica o farmacológica), y los que lo hacen sin elevación del segmento ST (SCASEST), que son tributarios de tratamiento anti-isquémico y valoración angiográfica preferente.

2. Electrocardiograma

2.1. Conceptos básicos

El ECG es la representación gráfica de la actividad eléctrica del corazón. La despolarización de las células cardiacas se realiza de una manera ordenada, comenzando en el nodo sinusal y propagándose secuencialmente hacia las aurículas, el nodo aurículo-ventricular (AV) y los ventrículos. Esta onda de despolarización genera un campo eléctrico que puede ser detectado mediante electrodos situados en la superficie corporal, generándose así la señal del ECG.

El potencial de reposo transmembrana es negativo, es decir, el interior celular es negativo y el exterior es relativamente positivo. Cuando se genera un estímulo eléctrico, se produce una entrada de sodio dentro de la célula, volviéndose el exterior negativo respecto al interior celular. Sin embargo, la sección de la membrana que aún no ha sido despolarizada permanece positiva respecto al interior celular. Consecuentemente, se establece un dipolo, cuya dirección corresponderá a la dirección de la carga positiva respecto a la negativa, y cuya magnitud dependerá del número de cargas positivas que entran en la célula (14-15).

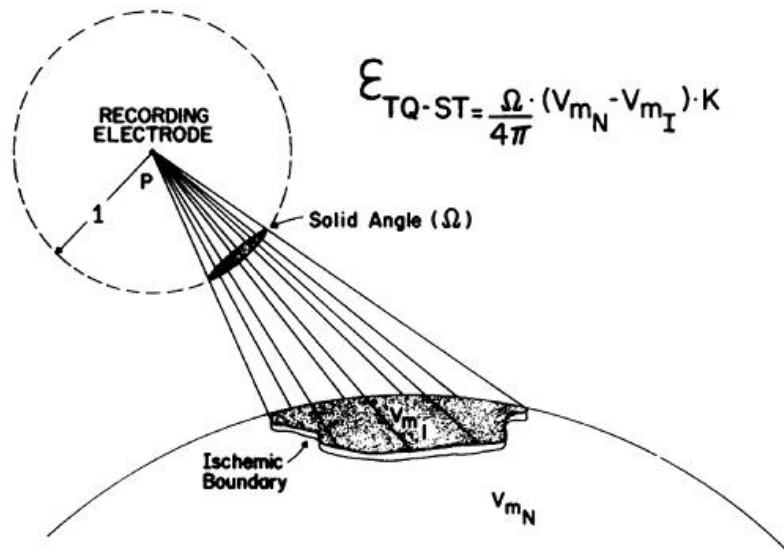


Figura 3. Representación gráfica y matemática de la teoría del ángulo sólido. Imagen tomada de Holland et al (16).

El registro de la actividad eléctrica se sustenta en la teoría del ángulo sólido, que permite calcular la magnitud de los potenciales proyectados sobre un punto alejado de un frente de ondas. Se denomina ángulo sólido de un punto con respecto a un cuerpo, a aquella porción de la superficie de una esfera imaginaria (cuyo radio es igual a la unidad y cuyo centro coincide con el punto explorador) limitada por todas las líneas rectas que cortando a la esfera, unan el punto explorador con los contornos del cuerpo a explorar (Figura 3). El teorema establece que el potencial registrado por un electrodo remoto (Φ) viene definido por la siguiente ecuación (16):

$$\Phi = \frac{\Omega}{4\pi} (V_{m2} - V_{m1}) K$$

Donde Ω es el ángulo sólido, $(V_{m2} - V_{m1})$ corresponde a la diferencia de potencial a ambos lados de la región estudiada, y K es una constante que refleja las diferencias en la conductividad intracelular.

Así el potencial registrado en el electrodo viene determinado por dos factores: el ángulo sólido, que se encuentra influenciado por parámetros espaciales (dimensiones de la región estudiada y posición del electrodo explorador), y la diferencia de potencial a través de la superficie, modificable por parámetros no espaciales (como por ejemplo la isquemia miocárdica) (16).

La activación eléctrica del corazón comienza en el nodo sinusal, cuyas células tienen la capacidad de despolarizarse espontáneamente (automatismo). El impulso se transmite a las aurículas a través de vías especializadas de conducción. La despolarización auricular genera en el ECG la onda P, y coincide con la contracción auricular. A partir de aquí el frente de activación alcanza el nodo AV, donde sufre un enlentecimiento en su propagación, que se corresponde en el ECG con el segmento PR. Finalmente la onda de despolarización se transmite a los ventrículos a través del sistema His-Purkinje, produciéndose una contracción ventricular ordenada que se refleja en el ECG mediante el complejo QRS. Tras la despolarización completa de ambos ventrículos, hay un periodo de tiempo en el que no se registra actividad eléctrica (segmento ST), coincidiendo con

la fase 2 (plateau) del potencial de acción, tras el cual se inicia la repolarización ventricular, generándose la onda T en el ECG.

El registro del ECG se realiza de forma estandarizada a través de 12 derivaciones: 6 derivaciones periféricas o de miembros, y 6 derivaciones precordiales. Las derivaciones periféricas se obtienen a partir de electrodos situados en ambas extremidades superiores y en la extremidad inferior izquierda (Figura 4). Se dividen en tres derivaciones bipolares (I, II, III), constituidas por la diferencia de potencial entre dos de los electrodos, y las derivaciones aumentadas (aVR, aVL, aVF), en las que la diferencia de potencial se establece entre cada uno de los electrodos y un electrodo de referencia (terminal central de Wilson) creado mediante la conexión de los tres electrodos de miembros, cuyo sumatorio es cero. En realidad, el electrodo de referencia para las derivaciones aumentadas es una modificación de la terminal central de Wilson que permite incrementar la amplitud de la señal registrada. Así, para cada derivación aumentada la diferencia de potencial se establece entre un electrodo de miembros y la media de los otros dos electrodos de miembros (17).

Las derivaciones precordiales (V1-V6) usan también la terminal central de Wilson como electrodo de referencia, situándose los electrodos exploradores en la región precordial, desde la región paraesternal hasta la línea media axilar izquierda (Figura 4).

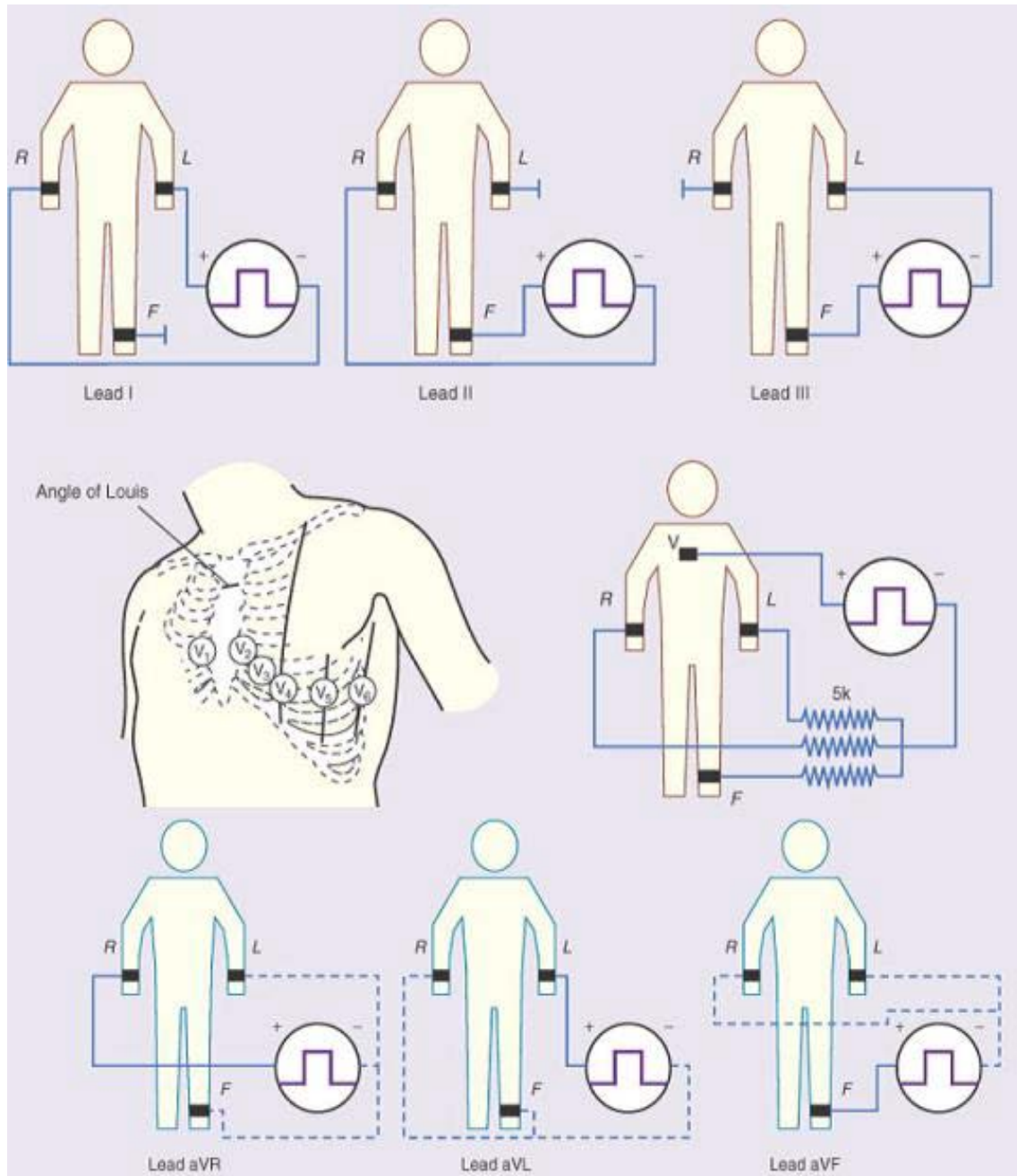


Figura 4. Derivaciones del electrocardiograma convencional. Representación gráfica de los electrodos entre los que se registra la señal eléctrica para cada una de las 12 derivaciones del electrocardiograma convencional. Imagen adaptada de Braunwald: Tratado de cardiología. Texto de medicina cardiovascular, 8ª edición.

Pueden emplearse además derivaciones adicionales en determinadas situaciones clínicas. Así, las derivaciones precordiales derechas (V3R-V4R) pueden ser de utilidad en el diagnóstico del infarto de ventrículo derecho, y las derivaciones posteriores (V7-V9) en el diagnóstico del infarto de cara inferobasal o posterior.

2.2. El electrocardiograma en la isquemia miocárdica

La isquemia miocárdica se produce como consecuencia de un desequilibrio entre las necesidades metabólicas y el aporte de oxígeno al miocardio. La interrupción brusca del flujo coronario, debida en la mayoría de los casos a una complicación trombótica de una placa aterosclerosa, conlleva alteraciones del ECG en el segmento ST, el complejo QRS y la onda T. La interrupción completa del flujo coronario da lugar a isquemia miocárdica transmural, mientras que si la interrupción es subtotal, la isquemia miocárdica se limita al subendocardio.

En condiciones normales, el segmento ST es relativamente isoelectrico debido a que todos los miocardiocitos alcanzan el mismo potencial de membrana durante la fase de meseta (fase 2 o plateau) del potencial de acción. Sin embargo, durante la isquemia miocárdica aguda se produce una reducción en el potencial de reposo transmembrana (que se hace menos negativo), un acortamiento en la duración del potencial de acción, una disminución de la velocidad de ascenso y amplitud de la fase 0, y una

modificación en la forma de la fase 2 del potencial de acción. Estos cambios crean un gradiente de potencial entre las áreas normal e isquémica, generándose un flujo de corriente entre ambas regiones, tanto en la fase sistólica (fase 2 del potencial de acción) como en la fase diastólica (potencial de reposo transmembrana) del ciclo cardiaco. Estas denominadas corrientes de lesión se registran en el ECG en forma de desviaciones del segmento ST respecto a su línea isoeletrica (Figura 5) (18-19).

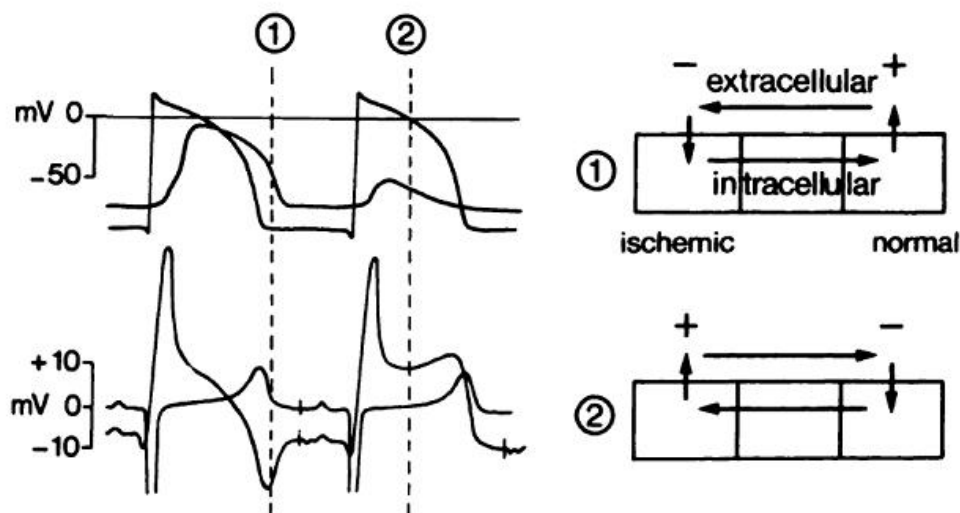


Figura 5. Registro del potencial de reposo transmembrana (parte superior izquierda) y del electrocardiograma (parte inferior izquierda) en situación basal y tras oclusión arterial coronaria. Diagrama de las corrientes de lesión generadas entre las regiones normal e isquémica (derecha). Imagen tomada de Cinca et al (19).

Si la isquemia miocárdica es transmural, la corriente de lesión generada en la sístole, secundaria a las alteraciones en la fase 2 del potencial de acción,

produce una elevación del segmento ST sobre la zona isquémica (y en ocasiones, aparición de ondas T picudas). Además, durante la diástole, la corriente de lesión, debida a las alteraciones en el potencial de reposo transmembrana, genera un descenso del segmento TQ (Figura 5). Sin embargo, debido a las características del registro del ECG, que utiliza amplificadores acoplados a corriente alterna para mantener una línea isoeléctrica estable durante la diástole, no pueden apreciarse las desviaciones del segmento TQ, registrándose una única elevación global del segmento ST que en realidad es la suma del ascenso del segmento ST y el descenso del segmento TQ. Si la isquemia es subendocárdica, se produce una depresión del segmento ST sobre la zona isquémica.

Acompañando al ascenso del segmento ST en las derivaciones del ECG que se enfrentan al área isquémica en el transcurso de un infarto transmural, puede además registrarse con frecuencia descenso del segmento ST en derivaciones opuestas. El mecanismo de estas alteraciones concomitantes del ECG, conocidas como cambios recíprocos o especulares, no es del todo bien conocido. Dos son las teorías que clásicamente se han empleado para explicar la presencia de dichos cambios recíprocos:

1. Proyección eléctrica pasiva de los cambios directos del segmento ST registrados en las derivaciones enfrentadas al área isquémica (20-26).

2. Presencia de isquemia subendocárdica a distancia añadida (27-29).

Adicionalmente, se observan cambios en el complejo QRS en las primeras fases de la isquemia miocárdica, consistentes en crecimiento de la onda R y alargamiento del complejo QRS. Estos cambios se deben a que en el área isquémica se produce un enlentecimiento de la velocidad de conducción local y un retraso en la activación celular (19).

Las alteraciones del segmento ST (y las ondas T picudas) son el primer signo de isquemia miocárdica aguda, y generalmente van seguidas de un periodo de horas o días en los que se observa una inversión evolutiva de la onda T, y a veces la aparición de una onda Q. La inversión de la onda T es debida a una mayor duración de los potenciales de acción, y puede desaparecer al cabo de días o semanas, o persistir de forma indefinida. La presencia de onda Q es indicativa de necrosis miocárdica (14-15).

2.3. Patrones electrocardiográficos en la isquemia miocárdica aguda: correlación eléctrica y anatómica

La utilidad del ECG en la cardiopatía isquémica no radica solamente en el diagnóstico de isquemia, sino que permite además hacer una aproximación sobre la localización del área miocárdica afectada y la arteria coronaria implicada en el evento.

De especial utilidad es la información recogida en el ECG en el transcurso de un SCACEST (isquemia transmural), ya que en función de las derivaciones afectadas se puede predecir la localización de la oclusión arterial coronaria.

Convencionalmente se han establecido dos áreas miocárdicas en riesgo (anteroseptal e inferolateral), con sus correspondientes correlaciones anatómicas y electrocardiográficas. La isquemia miocárdica de cara anterior, debida a oclusión de la arteria coronaria descendente anterior, se registra en el ECG como elevación del segmento ST en derivaciones precordiales (V1-V6). La isquemia miocárdica de cara inferior, debida a oclusión de la arteria coronaria circunfleja o de la arteria coronaria derecha, se manifiesta en el ECG como elevación del segmento ST en derivaciones inferiores (II, III, aVF), pudiendo verse afectadas también las derivaciones laterales (I, aVL, V5-V6) (30).

Adicionalmente, puede obtenerse una localización más precisa de la oclusión coronaria por los datos del ECG. Así, en los casos de isquemia anterior, la presencia de cambios recíprocos concomitantes en derivaciones inferiores es sugestiva de oclusión de la arteria descendente anterior previa al nacimiento de la rama diagonal (Figura 6), mientras que la ausencia de dichos cambios recíprocos indica afectación distal a la rama diagonal (Figura 7) (31-34).

Así mismo, la presencia de elevación del segmento ST en la derivación V1 es sugestiva de afectación de la arteria descendente anterior proximal a la rama septal (Figura 6), mientras que la ausencia de afectación de V1 indica oclusión distal a la rama septal (Figura 8) (31-32).

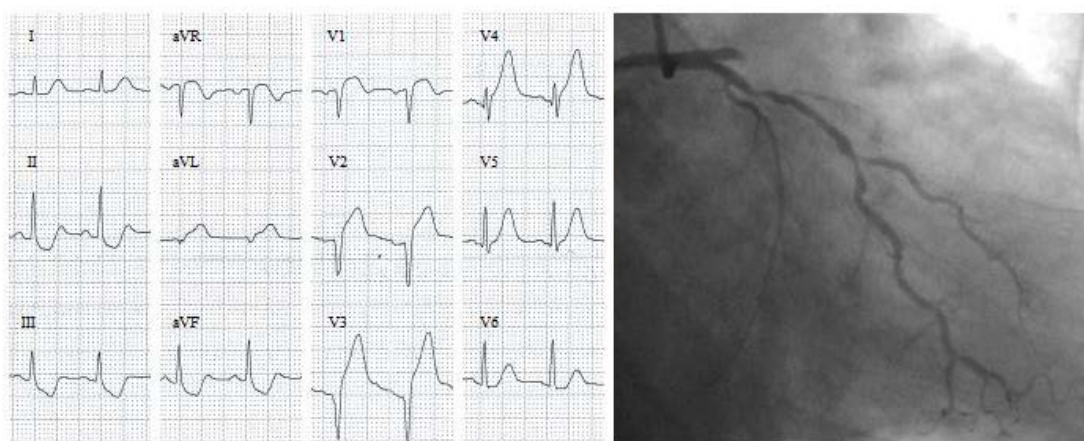


Figura 6. Registro electrocardiográfico de un paciente con infarto anterior por oclusión de la arteria descendente anterior proximal al nacimiento de las primeras ramas diagonal y septal.

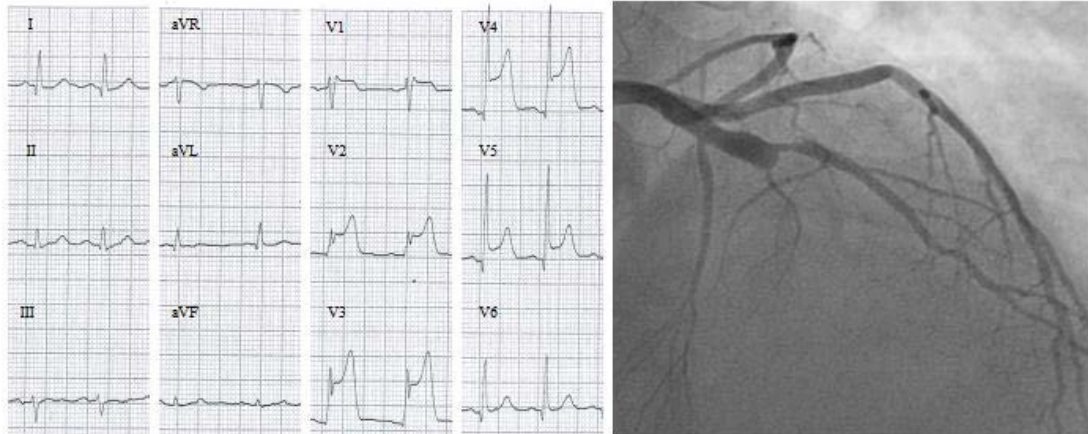


Figura 7. Registro electrocardiográfico de un paciente con infarto anterior por oclusión de la arteria descendente anterior distal al nacimiento de la primera rama diagonal.

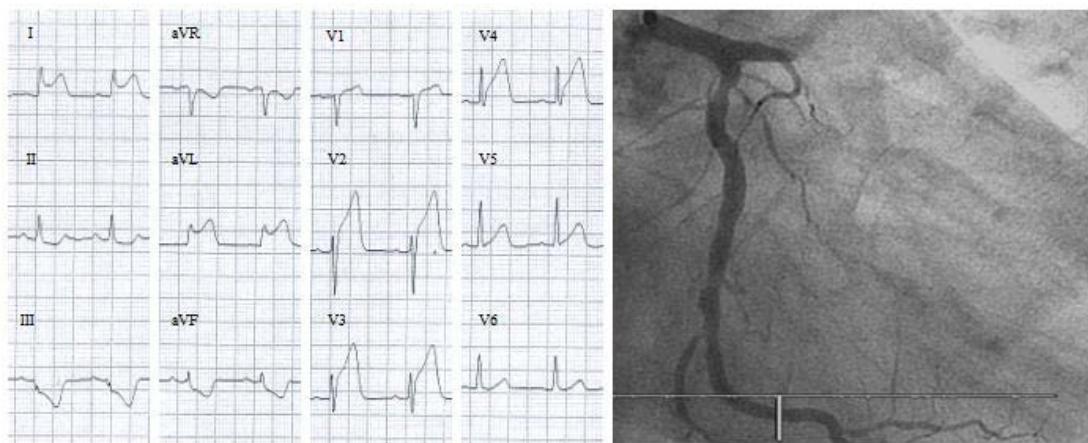


Figura 8. Registro electrocardiográfico de un paciente con infarto anterior por oclusión de la arteria descendente anterior distal al nacimiento de la primera rama septal.

En cuanto a la isquemia inferior, varios son los parámetros que se han empleado para intentar diferenciar la arteria enferma. Los hallazgos sugestivos de oclusión de la arteria coronaria derecha son la elevación del segmento ST en III mayor que en II, el descenso del segmento ST en I y la presencia de una mayor magnitud de los cambios directos (ascenso del segmento ST en derivaciones inferiores) respecto a los cambios recíprocos (descenso del segmento ST en V1-V3) (Figura 9) (35-36).

Por el contrario, la afectación de la arteria circunfleja suele presentar en el ECG una elevación del segmento ST en II mayor que en III, acompañada de una elevación también en I, y una mayor magnitud de los cambios recíprocos en V1-V3 respecto a los cambios directos en derivaciones inferiores (Figura 10) (35-36).

No obstante, todos estos patrones de correlación anatómica y electrocardiográfica han sido validados en situaciones de isquemia miocárdica con afectación exclusiva del vaso coronario responsable. Estos patrones podrían verse modificados en los casos en los que hubiera enfermedad coronaria significativa de más de un vaso coronario, es decir, si hubiera isquemia subendocárdica o subepicárdica añadida en más de un territorio de forma simultánea.

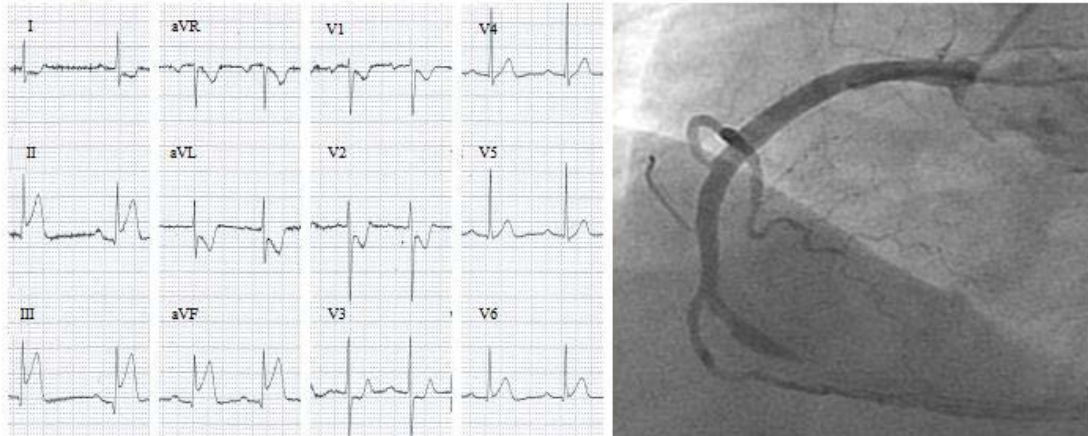


Figura 9. Registro electrocardiográfico de un paciente con infarto inferior por oclusión de la arteria coronaria derecha.

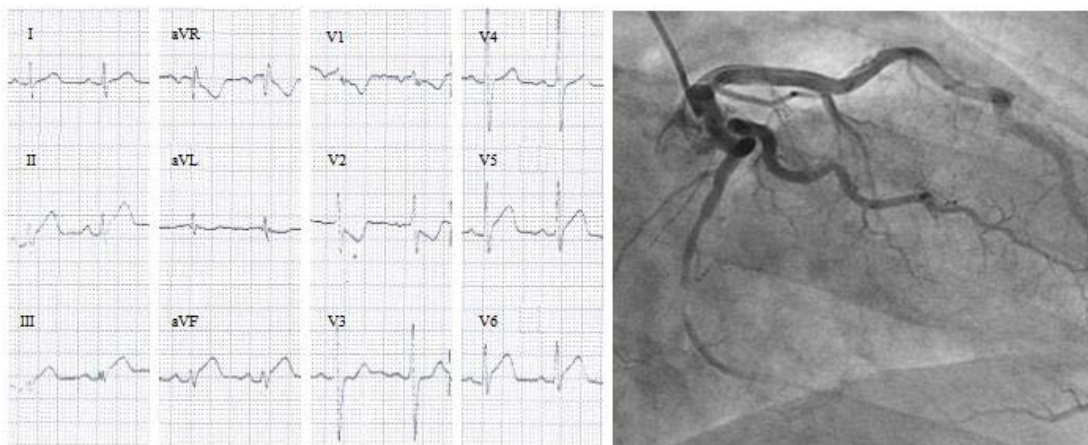


Figura 10. Registro electrocardiográfico de un paciente con infarto inferior por oclusión de la arteria circunfleja.

HIPÓTESIS Y OBJETIVOS

1. Hipótesis

1. La isquemia miocárdica transmural secundaria a oclusión coronaria aguda induce alteraciones recíprocas del segmento ST y del complejo QRS en derivaciones alejadas del área isquémica, sin necesidad de que exista isquemia subendocárdica concomitante a distancia.
2. La presencia de enfermedad coronaria multivaso podría modificar el patrón de cambios del segmento ST, y de esta forma los criterios clásicos de localización de la arteria coronaria responsable podrían no ser aplicables.
3. La isquemia miocárdica simultánea en dos regiones contrapuestas produce una cancelación de las alteraciones del segmento ST.

2. Objetivos

2.1. Objetivo general

Conocer mediante un estudio traslacional el significado clínico y mecanismo electrofisiológico de las alteraciones recíprocas del ECG durante la isquemia miocárdica aguda transmural secundaria a oclusión coronaria.

2.2. Objetivos específicos

2.2.1. Objetivos experimentales

- Analizar el mecanismo de las alteraciones recíprocas del segmento ST en un modelo experimental porcino de oclusión coronaria aguda a distintos niveles.
- Discernir si las alteraciones recíprocas del segmento ST se asocian a alteraciones recíprocas del complejo QRS.
- Analizar si la isquemia miocárdica en regiones opuestas cancela los cambios directos y recíprocos del segmento ST.

2.2.2. Objetivos clínicos

- Caracterizar las alteraciones recíprocas del segmento ST en pacientes que presentan oclusión aguda de una arteria coronaria, y correlacionar dichas alteraciones con la localización de la oclusión coronaria.
- Analizar si los patrones de las alteraciones recíprocas del segmento ST se modifican en pacientes con alteración coronaria multivaso.

RESULTADOS

1. **Artículo 1: Mechanism and diagnostic potential of reciprocal ECG changes induced by acute coronary artery occlusion in pigs.** Francisco Javier Noriega, Esther Jorge, Dabit Arzamendi, Juan Cinca. Heart Rhythm. 2013;10:883-890.

Mechanism and diagnostic potential of reciprocal ECG changes induced by acute coronary artery occlusion in pigs

Francisco J. Noriega, MD, Esther Jorge, DVM, PhD, Dabit Arzamendi, MD, Juan Cinca, MD, PhD

From the Department of Cardiology, Hospital de la Santa Creu i Sant Pau, Institute of Biomedical Research (IIB-Sant Pau), Universitat Autònoma de Barcelona, Barcelona, Spain.

BACKGROUND Reciprocal ST-segment depression simulating additional subendocardial ischemia is commonly observed in ST-segment elevation myocardial infarction.

OBJECTIVE To study the mechanism and characterization of the whole reciprocal electrocardiogram (ECG) patterns induced by acute coronary artery occlusion at different locations in the absence of additional subendocardial ischemia in pigs.

METHODS Conventional 12-lead ECG and/or local extracellular epicardial, mid-myocardial, and endocardial electrograms were recorded during the acute occlusion of right coronary (RC) and left anterior descending (LAD) coronary arteries in the in situ ($n = 9$) or in the isolated perfused ($n = 5$) pig hearts.

RESULTS Mid-RC occlusion induced reciprocal ST-segment depression (-0.43 ± 0.14 mV; $P < .01$) and S-wave deepening (-0.74 ± 0.23 mV; $P < .01$) in anterior ECG leads. Mid-LAD occlusion induced reciprocal S-wave deepening (-0.43 ± 0.37 mV; $P = .02$) but not ST-segment depression in inferior leads. Proximal LAD induced reciprocal ST-segment depression (-0.21 ± 0.20 mV; $P = .03$) and S-wave deepening (-0.56 ± 0.58 mV; $P = .04$) in

inferior leads. Reciprocal QRS widening was observed only during proximal LAD occlusion. Local extracellular recordings did not show significant reciprocal QRS and ST-segment changes.

CONCLUSIONS In the absence of additional subendocardial ischemia, acute coronary artery occlusion induces reciprocal ST-segment and S-wave changes in the 12-lead ECG that allow better differentiation between proximal and mid-LAD occlusion. Reciprocal ECG changes depend on conventional lead system design and not on the transmission of injury currents from the ischemic border zone to distant normal myocardium.

KEYWORDS Myocardial ischemia; Coronary occlusion; Reciprocal ECG changes; In situ heart; Isolated perfused heart; Pigs

ABBREVIATIONS ECG = electrocardiogram; LAD = left anterior descending; LV = left ventricle/ventricular; QTc = corrected QT interval; RC = right coronary

(Heart Rhythm 2013;10:883–890) © 2013 Heart Rhythm Society. All rights reserved.

Introduction

Acute transmural myocardial ischemia induces ST-segment elevation, enlargement of the R wave, and widening of the QRS complex (monophasic potentials) in the electrocardiogram (ECG) leads directly related to the ischemic region.^{1–3} Moreover, leads not related to the ischemic area can show concurrent reciprocal ST-segment depression.^{4–6} Two major mechanisms have been proposed to explain the reciprocal ST-segment changes: a passive reflection of leads with ST-segment elevation^{7–11} or concomitant subendocardial ischemia at a distance of the transmural injury.^{12–14}

This work was supported by Spanish Fundació Marató TV3 (grant no. 080630-2007) and Redes Temáticas de Investigación Cooperativa en Salud del Instituto de Salud Carlos III (REDINSCOR, grant no. RD06-0003-0000). **Address for reprint requests and correspondence:** Dr Francisco J. Noriega, Department of Cardiology, Hospital de la Santa Creu i Sant Pau, Institute of Biomedical Research (IIB-Sant Pau), Universitat Autònoma de Barcelona, St. Antoni M. Claret, 167, 08025 Barcelona, Spain. E-mail address: fnoriega@santpau.cat.

Distinction between the 2 mechanisms in patients with acute myocardial ischemia is uncertain, because the reciprocal ECG patterns are not yet well known. Indeed, if reciprocal ST-segment depression was in fact a mere reflection of leads with ST-segment elevation, then it should be proven that the reciprocal ST-segment changes are not present in local extracellular recordings obtained at distant nonischemic myocardial regions. Moreover, the reciprocal changes can involve not only the ST segment but also the QRS complex since the enlargement of the R wave generated in the ischemic area³ could give rise to reciprocal S-wave deepening in non-ischemic-related leads. In addition, analysis of the reciprocal ECG changes in combination with the classical ST-segment elevation pattern can improve the predictive diagnosis of the location of coronary occlusion.

Therefore, this study was undertaken to elucidate the mechanism and characterization of the whole reciprocal ECG changes induced by acute occlusion of the right and left coronary arteries in a porcine model free of additional subendocardial ischemia at a distance of the injured region.

Epicardial and endocardial extracellular electrograms were recorded in the in situ and the isolated perfused pig heart to assess the occurrence of reciprocal ECG changes.

Methods

Study population

Fourteen large white pigs weighing 40 kg were sedated with azaperone (8 mg/kg intramuscularly; Stressnil, Esteve Farma SA, Barcelona, Spain) and anesthetized with sodium tiopental (10 mg/kg intravenously; Pentothal, B. Braun Medical SA, Barcelona, Spain). They were intubated and mechanically ventilated with a mixture of oxygen and 2% isoflurane to maintain general anesthesia. Buprenorphine (0.01 mg/kg intravenously; Buprex, Schering-Plough SA, Madrid, Spain) and atracurium besylate (1 mg/kg intravenously; Tracrium, GlaxoSmithKline SA, Madrid, Spain) were administered during the procedure for analgesia and muscular relaxation, respectively.

The study protocol was approved by the ethics and animal welfare committee of our institution according to the regulation for the treatment of animals established by the *Guide for the Care and Use of Laboratory Animals* published by the US National Institutes of Health (NIH Publication No. 85-23, revised 1996).

Experimental series

In situ heart

All animals included in the study were free of significant atherosclerotic coronary artery disease as denoted by coronary angiography. Thus, the reciprocal changes induced by coronary artery occlusion in this model cannot be attributed to concomitant subendocardial ischemia.

Coronary artery occlusion. Acute transmural myocardial ischemia was induced by percutaneous coronary catheter balloon occlusion. The 2 femoral arteries were catheterized and 2 7-F introducers were used to insert 6-F guide catheters (Merit Medical Europe, Maastricht, The Netherlands). Under fluoroscopy control, the catheters were advanced to the ostium of the right and left coronary arteries. Then, 2 coronary catheters with a 3 mm balloon (Maverick, Boston, MA) were positioned at the proximal or mid-segments of the right coronary (RC) or left anterior descending (LAD) coronary artery. The position of the catheter balloon was verified by using coronary angiography. The arterial pressure was monitored in both catheters, and arterial wave dumping was not observed, suggesting that the catheter was not occlusive. In addition, the baseline ECG showed the absence of ST-segment deviation. Coronary occlusion was induced by transient (5 minutes) inflation of the balloon at 12 atm. Immediately after balloon inflation, a contrast injection was performed in both coronary arteries to assess the absence of flow in the occluded artery and normal flow in the non-occluded contralateral artery. Sodium heparin (70 U/kg,

bolus injection) was given to prevent thrombus formation during the procedure.

Conventional 12-lead ECG. The 12-lead ECG was recorded and stored on a hard disk of a multichannel recording system (Prucka Engineering, Inc, Houston, TX). Because of species anatomy, the precordial leads were placed 1 intercostal space above that used in current clinical electrocardiography. In each ECG recording, we measured the magnitude of the ST-segment deviation at the J point level, the amplitude of R and S waves, the duration of the QRS complex, and the duration of the QT interval. The correction of the QT interval (QTc) for the heart rate was made according to the Bazget formula: $QTc = QT/\sqrt{RR}$.

Transmural local electrograms. A midsternotomy was performed to expose the heart. Then, transmural needles containing 3 electrodes (3-mm interelectrode distance) were inserted into the anterior left ventricle (LV) free wall, allowing recording of epicardial, mid-myocardial, and endocardial local electrograms. The reference electrode was placed at the border of the midsternotomy. Signals were recorded by using a BioSemi Mark-V acquisition system (Amsterdam, The Netherlands). A waiting period of 60 minutes was followed in order to allow healing of the injury caused during the insertion of electrodes. Local electrograms that did not recover were excluded from the study. An off-line analysis of each recorded local electrogram was done with a custom-made data analysis program for the following parameters: ST-segment deviation measured at the J point level, R- and S-wave amplitude, and QRS complex duration.

Study protocol. In 7 pigs, we recorded the 12-lead ECG at baseline and continuously during 5 minutes of single coronary artery occlusion at 3 different locations spaced by 10 minutes of coronary reperfusion: (1) mid-segment of the RC, (2) mid-segment of the LAD, and (3) proximal segment of the LAD. In order to assess whether the reciprocal ST-segment changes are also present in local electrograms in the in situ heart, we simultaneously recorded the 12-lead ECG and the local transmural electrograms in the anterior LV region in 2 additional pigs submitted to mid-RC catheter balloon occlusion.

Isolated Langendorff perfused heart

This model was used to assess whether the reciprocal ST-segment changes are present in the nonischemic regions of the isolated perfused heart. A midsternotomy was performed to expose the heart. After administration of intravenous sodium heparin (70 U/kg, bolus injection), 1000 mL of blood was collected. Then, the heart was removed and rapidly immersed in cold Tyrode's solution. The aorta was cannulated and connected to a Langendorff perfusion setup filled with the extracted blood. The circulating blood was oxygenated with a mixture of 95% O₂ and 5% CO₂ by using a clinical extracorporeal oxygenator (Palex SA, Barcelona,

Spain), and the temperature was kept between 36.5 and 37°C. Samples of the circulating blood were obtained to keep blood gases and pH at normal values.

Coronary artery occlusion. The LAD was dissected at its proximal segment above the origin of the first diagonal branch and was looped with a 3/0 Prolene suture. The 2 ends of the suture were threaded through a smooth plastic tube, and the artery was acutely occluded by sliding the tubing over the suture and clamping it with a small hemostat. Reperfusion was accomplished by releasing the ligature.

Transmural local electrograms. Fifteen transmural needles containing 3 electrodes spaced 3 mm were inserted in the heart in a circumferential row covering the anterior, lateral, and posterior regions of the LV, with an interelectrode distance of about 2 cm. The reference electrode was placed in the aortic root.

Study protocol. Five animals were included in this series. After placing the heart into the perfusion system, a direct current electrical shock of 15 J was applied to defibrillate the heart. Then, the LAD was dissected to place the occluding snare and the transmural needle electrodes were inserted. Recordings of all local electrograms were performed at baseline and continuously during 5 minutes of proximal LAD occlusion.

Data analysis. Data are presented as mean \pm SD. The statistical significance of the ECG changes from baseline to 5 minutes of coronary occlusion was assessed by using either the paired samples *t* test or the 1-way repeated measures analysis of variance with the software PASW statistics 18.0 (SPSS Inc, Chicago, IL). A *P* value of $<.05$ was considered statistically significant.

Results

In situ heart data

Changes in ST-segment potential

Figure 1A illustrates the ST-segment changes induced after 5 minutes of single coronary artery occlusion at different segments of the RC and LAD in 7 pigs. Mid-RC occlusion induced ST-segment elevation in inferior leads (maximal in lead III: 0.20 ± 0.10 mV; $P < .01$) and ST-segment depression in leads V_2 – V_6 and aVL (maximal in lead V_4 : -0.43 ± 0.14 mV; $P < .01$). Mid-LAD occlusion induced ST-segment elevation in leads V_1 – V_5 (maximal in lead V_3 : 0.94 ± 0.34 mV; $P < .01$), but failed to induce significant reciprocal ST-segment depression. Proximal LAD occlusion induced ST-segment elevation in leads V_1 – V_6 and aVL (maximal in lead V_4 : 0.96 ± 0.36 mV; $P < .01$) associated with ST-segment depression in inferior leads (maximal in lead III: -0.21 ± 0.20 mV; $P = .03$).

Changes in RS-wave amplitude

Figure 1B illustrates the changes in RS-wave amplitude from baseline to 5 minutes of RC and LAD occlusion at different locations in 7 pigs. Mid-RC occlusion induced R-wave enlargement in inferior leads (maximal in lead III: 0.67 ± 0.51 mV; $P = .01$) and S-wave deepening in leads V_2 – V_6 and in lateral leads (maximal in lead V_4 : -0.74 ± 0.23 mV; $P < .01$). Mid-LAD occlusion induced R-wave enlargement in leads V_1 – V_5 (maximal in lead V_3 : 2.90 ± 0.57 mV; $P < .01$) and S-wave deepening in inferior leads (maximal in lead II: -0.43 ± 0.37 mV; $P = .02$). Proximal LAD occlusion induced R-wave enlargement in leads V_1 – V_6 (maximal in lead V_4 : 3.66 ± 0.50 mV; $P < .01$) and S-wave deepening in inferior leads (maximal in lead III: -0.56 ± 0.58 mV; $P = .04$).

Changes in QRS complex duration

Figure 2 illustrates the QRS widening from baseline to 5 minutes of RC and LAD occlusion at different locations in 7 pigs. Baseline QRS complex duration was 0.06 ± 0.01 seconds for limb leads and 0.07 ± 0.01 seconds for precordial leads. Mid-RC occlusion induced QRS complex widening in inferior leads (maximal in lead II: 0.02 ± 0.01 seconds; $P < .01$) but a nonsignificant prolongation in precordial and lateral leads. Mid-LAD occlusion induced QRS complex widening in leads V_1 – V_6 (maximal in lead V_4 : 0.05 ± 0.04 seconds; $P = .01$) and in lateral leads (maximal in lead aVL: 0.01 ± 0.01 seconds; $P = .02$) but nonsignificant changes in inferior leads. Proximal LAD occlusion induced QRS complex prolongation in all leads except aVR (maximal in lead V_4 : 0.07 ± 0.03 seconds, $P < .01$; lead I: 0.04 ± 0.03 seconds, $P = .01$; lead III: 0.03 ± 0.02 seconds, $P = .01$).

Figure 3 illustrates the QRS and ST-segment changes in a pig submitted to single occlusion of the mid-RC and proximal and mid-LAD.

Changes in QT interval

There were not significant differences in QT interval duration among the 12-lead ECG at baseline (mean QTc 0.51 ± 0.05 seconds). Five minutes after coronary occlusion, the QT interval tended to shorten in all leads but this trend was not statistically significant: mean QTc was 0.46 ± 0.05 seconds after RC occlusion, 0.49 ± 0.06 seconds after mid-LAD occlusion, and 0.47 ± 0.03 seconds after proximal LAD occlusion.

Time course of the ECG changes

The direct and reciprocal changes in ST segment and RS-wave amplitude induced by RC and LAD occlusion in 7 pigs began simultaneously and followed a parallel trend with an immediate recovery upon coronary reperfusion. Likewise, the prolongation of the QRS complex during proximal LAD occlusion in ischemic- and non-ischemic-related leads also followed a parallel trend (**Figure 4**).

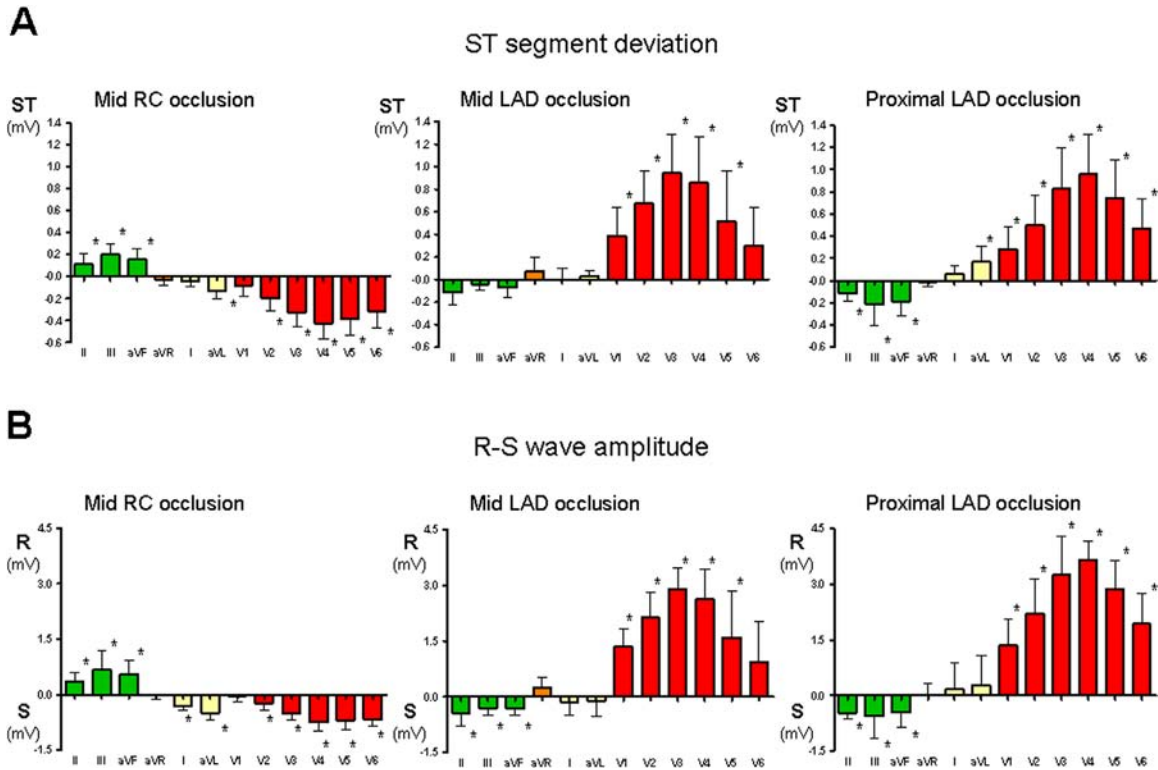


Figure 1 ST-segment and RS-wave changes induced by acute coronary artery occlusion in the in situ pig heart. Bars indicate the mean \pm SD values of the ST-segment potential (A) and RS-wave amplitude (B) in the 12-lead electrocardiogram induced after 5 minutes of catheter balloon occlusion of the mid-right coronary (RC), mid-left anterior descending (LAD), and proximal LAD in 7 pigs. * $P < .05$.

Simultaneous recordings of 12-lead ECG and transmural local electrograms

In 2 pigs submitted to mid-RC occlusion, the 12-lead ECG showed reciprocal ST-segment depression in precordial leads whereas the simultaneously recorded epicardial and endocardial electrograms in the anterior LV region failed to show ST-segment deviation (Figure 5).

Isolated Langendorff perfused heart data

Proximal LAD occlusion in 5 isolated hearts induced ST-segment elevation in epicardial (3.20 ± 1.60 mV; $P = .01$), mid-myocardial (4.00 ± 1.90 mV; $P < .01$), and

endocardial (3.80 ± 1.50 mV; $P = .02$) local electrograms at the anterior LV wall. By contrast, reciprocal ST-segment changes were not observed in lateral or in posterior LV regions (Figure 6). Moreover, R-wave enlargement in the anterior region (epicardial: 9.40 ± 3.80 mV, $P < .01$; mid-myocardial: 11.40 ± 5.60 mV, $P = .01$; endocardial: 9.00 ± 7.00 mV, $P = .08$) was not associated with a significant S-wave deepening in lateral or posterior LV wall. The prolongation of the QRS complex in the anterior LV region (epicardial: 0.008 ± 0.004 seconds, $P = .02$; mid-myocardial: 0.008 ± 0.004 seconds, $P = .02$; endocardial: 0.007 ± 0.005 seconds, $P = .06$) was not accompanied by QRS complex widening in lateral or posterior LV areas.

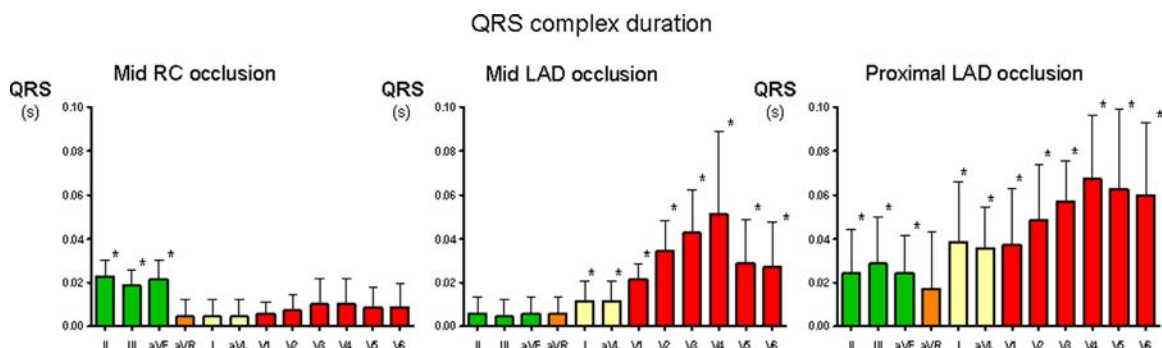


Figure 2 Changes in QRS complex duration induced by acute coronary artery occlusion in the in situ pig heart. Bars indicate the mean \pm SD values of the QRS complex duration in the 12-lead electrocardiogram induced after 5 minutes of catheter balloon occlusion of the mid-right coronary (RC), mid-left anterior descending (LAD), and proximal LAD in 7 pigs. * $P < .05$.

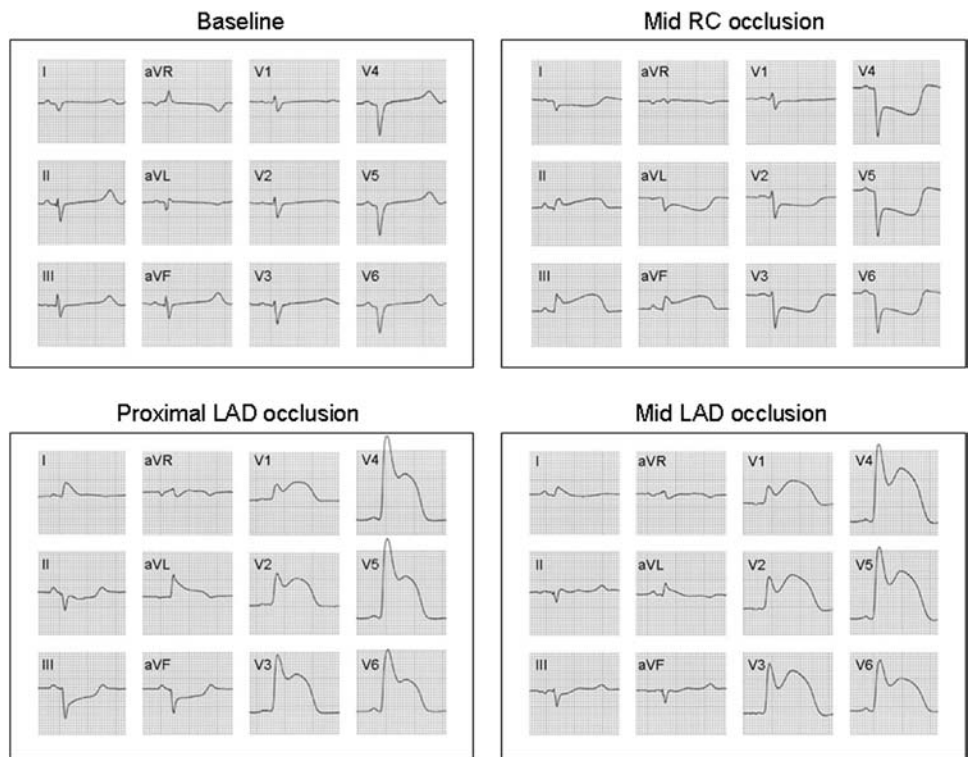


Figure 3 Representative 12-lead electrocardiogram (ECG) changes induced by acute coronary artery occlusion in the in situ pig heart. The figure shows the 12-lead ECG recordings at baseline and after 5 minutes of catheter balloon occlusion of the mid-right coronary (RC), proximal left anterior descending (LAD), and mid-LAD occlusion in 1 pig.

Discussion

Main findings

This study shows that in a pig heart model free of additional subendocardial ischemia, acute coronary artery occlusion elicits reciprocal ST-segment depression and S-wave deepening in ECG leads overlying distant nonischemic areas, although these changes were not appreciated in local extracellular electrograms directly recorded in the nonischemic myocardial regions. Moreover, we observe that the prolongation of QRS complex duration in ECG leads overlying the injured region is not accompanied by QRS widening in non-ischemic-related leads unless a large ischemic area is created by proximal LAD occlusion. Reciprocal ECG changes permitted a more accurate diagnostic prediction of the site of coronary occlusion.

Pattern of reciprocal ischemic ECG changes

Following the observations by Wolferth et al,⁴ depression of the ST segment in ECG leads overlying the nonischemic area emerged as a well-recognized reciprocal ECG pattern in patients with acute transmural myocardial infarction.^{5,6} Two mechanisms have been proposed to explain the reciprocal ST-segment depression⁷: (1) distant reflection of the ST-segment elevation generated in the ischemic region and (2) true ST-segment deviation caused by added local subendocardial ischemia. In our study, the distant reflection appeared to be the most likely mechanism because our pigs had no significant atherosclerotic coronary disease and therefore coronary occlusion in this model should not produce additional subendocardial ischemia at a distance of the region supplied by the occluded artery.

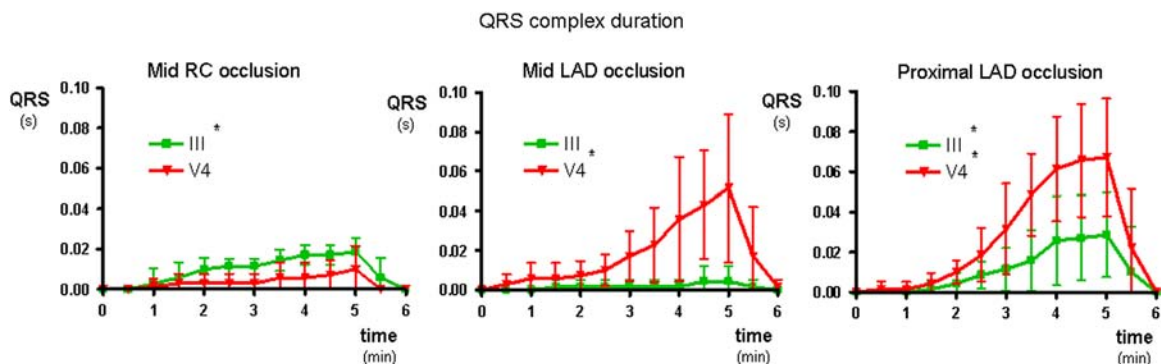


Figure 4 Sequential changes in QRS complex duration induced by acute coronary artery occlusion in the in situ pig heart. The figure shows the sequential mean \pm SD values of the QRS complex duration recorded in leads III (square symbol) and V₄ (triangle) induced during 5 minutes of catheter balloon occlusion of the mid-right coronary (RC), mid-left anterior descending (LAD), and proximal LAD, followed by 1 minute of reperfusion, in 7 pigs. **P* < .05 (analysis of variance).

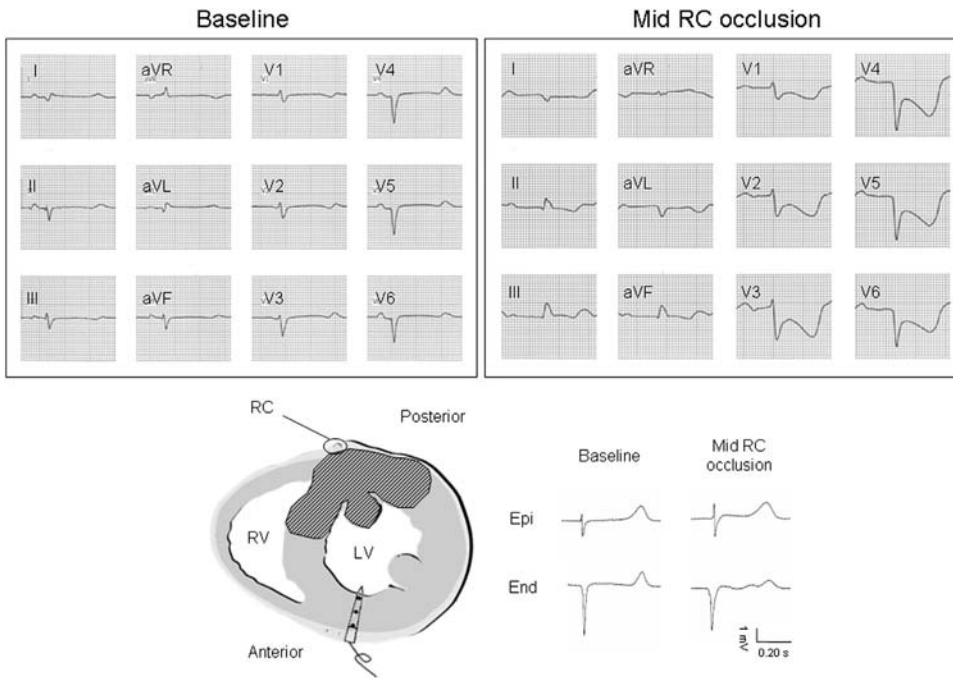


Figure 5 Simultaneous recording of 12-lead electrocardiogram (ECG) and local extracellular electrograms during mid-right coronary occlusion in the in situ pig heart. The figure shows simultaneous recording of the 12-lead ECG and epicardial (Epi) and endocardial (End) electrograms from the anterior left ventricular region in 1 pig submitted to mid-right coronary (RC) occlusion. Marked reciprocal ST-segment depression is observed in precordial ECG leads but not in the local electrograms. LV = left ventricle; RV = right ventricle.

Injury currents generated by membrane potential differences at the border zone between normal and ischemic (depolarized) myocardial cells are responsible for the ST-segment elevation in local extracellular electrograms^{3,15} and in the ECG leads overlying the ischemic region.

According to the solid angle theory,^{16,17} the ST-segment potential (ϵ_{ST}) recorded by an exploring electrode is

$$\epsilon_{ST} = \Omega/4\pi(V_{mI} - V_{mN})K$$

where Ω is the solid angle formed by lines from the recording electrode to every point along the ischemic boundary, V_{mI} and V_{mN} are the transmembrane potentials at ischemic and normal regions, and K is a constant correcting for differences in intracellular and extracellular conductivity and occupancy of the heart muscle by interstitial tissue and space.¹⁶ The magnitude of the solid angle varies directly with the radius of the ischemic boundary and inversely with the distance between the boundary and the recording point. This model predicts that the solid angle in precordial sites is maximal when the exploring electrode directly overlies the ischemic area and negative values can occur when the electrode moves at a considerable distance from the ischemic border zone.¹⁷ By contrast, the solid angle at the epicardial sites shows an abrupt change at the border zone and a rapidly decreasing negativity as the electrode moves further away from the boundary toward the nonischemic region.¹⁷ In agreement with these mathematical predictions, our study reveals that the ECG leads overlying distant nonischemic regions depict reciprocal ST-segment changes whereas local extracellular recordings obtained in similar distant normal regions failed to show appreciable reciprocal ST-segment depression. Therefore, our data support the concept that the reciprocal ST-segment changes induced during acute coronary occlusion are linked to the conventional ECG lead system design and not to a true propagation of the injury currents from the ischemic border zone to distant normal myocardial regions.

Acute myocardial ischemia slows down the propagation of the local activation front, and this is manifested by the

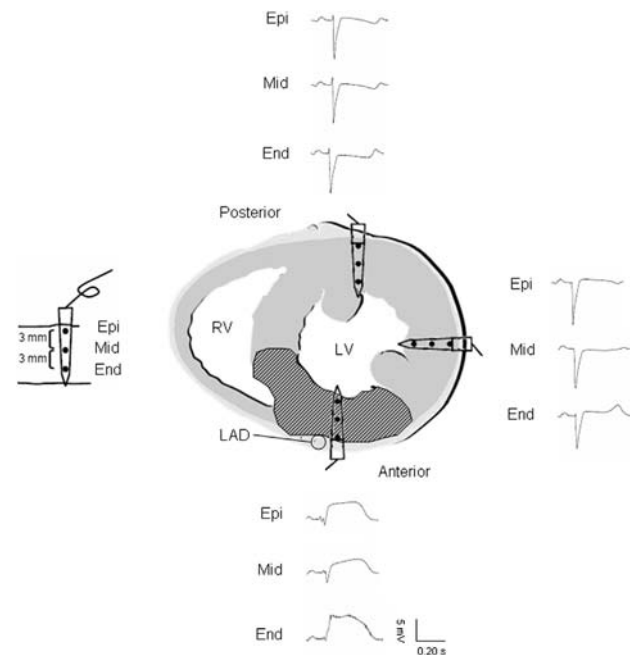


Figure 6 Changes in local extracellular electrograms during proximal left anterior descending coronary artery occlusion in the isolated perfused heart. The figure shows the epicardial (Epi), mid-myocardial (Mid), and endocardial (End) local electrograms from anterior, lateral, and posterior left ventricular regions after 5 minutes of proximal left anterior descending (LAD) ligation in 1 isolated pig heart. LV = left ventricle; RV = right ventricle.

enlargement of the R wave and widening of the QRS complex in local electrograms.³ The reciprocal increase in the S-wave amplitude observed in our study in the ECG leads overlying the nonischemic region could be considered as a reciprocal projection of the R-wave enlargement generated in the ischemic region. In fact, the solid angle predictions made for the ST-segment changes could also apply for the reciprocal RS-wave potential patterns because reciprocal S-wave changes were well detected in the peripheral ECG but were negligible in local extracellular recordings at distant nonischemic myocardial regions. The assessment of reciprocal S-wave changes in patients with acute myocardial ischemia is often limited by the lack of a previous baseline ECG. However, ECG recordings obtained in patients with coronary vasospasm before and during the episode of transmural myocardial ischemia do show reciprocal S-wave enlargement in the non-ischemic-related leads.^{2,3}

The prolongation of the QRS complex duration was more marked in leads overlying the ischemic region than in leads overlying the nonischemic myocardium, but widening of the QRS complex in these 2 regions attained a comparable magnitude when extensive myocardial ischemia was induced by proximal LAD occlusion. In an experimental study in pigs,¹⁸ the prolongation of the QRS complex in leads with ST-segment elevation differentiated transmural injury produced by acute coronary occlusion from epicardial injury free of local intramural conduction delay. The clinical value of QRS complex prolongation to differentiate acute transmural myocardial ischemia from acute pericarditis warrants further validation with specific clinical studies.

In the present study, we have observed a trend toward a QTc shortening after 5 minutes of occlusion of either the RC or the LAD in all 12 ECG leads. Acute myocardial ischemia is known to abbreviate the action potential duration of the injured cells, and this is reflected by a parallel QT interval shortening in the local extracellular electrograms.¹⁵ Likewise, studies in patients with acute transmural myocardial infarction have also found reduction in QT interval length during the first 12 hours, but in contrast to the porcine model, the QT interval shortening in humans was more apparent in the ECG leads overlying the ischemic region than in leads not related to the ischemic area.¹⁹ Differences in the QT response between both species could be explained, among others, by the different distribution of the Purkinje system (endo-epicardial in humans and transmural in pigs).

Dependence of reciprocal changes on the site of coronary occlusion

This study shows that the combined analysis of direct and reciprocal ST-segment changes predicts the site of coronary occlusion more accurately than the single analysis of the direct ST-segment elevation pattern. Indeed, whereas both proximal and mid-occlusions of the LAD induced a similar ST-segment elevation pattern in precordial leads, only the proximal LAD occlusion induced significant reciprocal ST-

segment depression in inferior leads. These findings are in agreement with previous clinical observations.²⁰

Clinical implications

Extrapolation of our model to clinical pathophysiology is based on several circumstances. First, the electrophysiological derangements induced by acute coronary artery occlusion in swine are comparable to those induced in humans.³ Second, the reciprocal ST-segment changes induced by acute coronary artery occlusion are not at variance with observations in humans.^{5,8,11,20}

The clinical significance of reciprocal ST-segment changes has not been entirely elucidated because human studies have been conducted in heterogeneous conditions. Some studies recruited patients with multiple vessel coronary disease, thus likely having added subendocardial ischemia at a distance of the transmural injury.¹²⁻¹⁴ In other instances, the time elapsed from the onset of the symptoms to the performance of coronary angiography ranged from 1 day to several months²⁰⁻²² and coronary reperfusion therapy varied from fibrinolytics²¹⁻²³ to primary coronary angioplasty.^{24,25}

Our study affords a comprehensive approach to the mechanism and whole characterization of the ECG changes induced during acute coronary occlusion in leads overlying nonischemic regions. It strengthens the concept that the reciprocal changes are not caused by added subendocardial ischemia and that combined analysis of direct and reciprocal ECG patterns allows identifying extensive LV anterior ischemia. In addition, it provides the foundation to a potential value of QRS complex duration changes to differentiate acute transmural myocardial ischemia from acute pericarditis.

Conclusions

Reciprocal ECG changes induced during acute coronary artery occlusion in a porcine model free of additional subendocardial ischemia involve the ST segment and the S wave and help predict the location of the occlusion. Reciprocal ST-segment depression is recorded in ECG leads overlying distant nonischemic regions, but is not apparent in extracellular electrograms also recorded at distant normal regions. Therefore, reciprocal ST-segment changes are linked to the conventional ECG lead system design and not to the true propagation of injury currents from the ischemic border zone to distant normal myocardial regions.

Acknowledgements

We appreciate the technical assistance provided by Roser Martínez.

References

1. Pardee HE. An electrocardiographic sign of coronary artery obstruction. *Arch Intern Med* 1920;26:244.
2. Alzamora-Castro V, Battilana G, Abugattas R. The electrical manifestations observed in damaged or injured cardiac muscle: an experimental study. *Am Heart J* 1957;54:254-263.
3. Cinca J, Janse MJ, Moréna H, Candell J, Valle V, Durrer D. Mechanism and time course of the early electrical changes during acute coronary artery occlusion: an

- attempt to correlate the early ECG changes in man to the cellular electrophysiology in the pig. *Chest* 1980;77:499–505.
4. Wolfarth CC, Bellet S, Livezey MM, Murphy FD. Negative displacement of the RS-T segment in the electrocardiogram and its relationships to positive displacement: an experimental study. *Am Heart J* 1945;29:220–245.
 5. Camara EJ, Chandra N, Ouyang P, Gottlieb SH, Shapiro EP. Reciprocal ST change in acute myocardial infarction: assessment by electrocardiography and echocardiography. *J Am Coll Cardiol* 1983;2:251–257.
 6. Pichler M, Shah PK, Peter T, et al. Wall motion abnormalities and electrocardiographic changes in acute transmural myocardial infarction: implications of reciprocal ST segment depression. *Am Heart J* 1983;106:1003–1009.
 7. Mirvis DM. Physiologic bases for anterior ST segment depression in patients with acute inferior wall myocardial infarction. *Am Heart J* 1988;116:1308–1322.
 8. Becker RC, Alpert JS. Electrocardiographic ST segment depression in coronary heart disease. *Am Heart J* 1988;115:862–868.
 9. Brymer JF, Khaja F, Marzilli M, Goldstein S. “Ischemia at a distance” during intermittent coronary artery occlusion: a coronary anatomic explanation. *J Am Coll Cardiol* 1985;6:41–48.
 10. Celik S, Yilmaz R, Baykan M, Orem C, Erdöl C. Are reciprocal changes a consequence of “ischemia at a distance” or merely a benign electrical phenomenon? A pulsed-wave tissue Doppler echocardiographic study. *Ann Noninvasive Electrocardiol* 2003;8:302–307.
 11. Rude RE, Croft CH, Willerson JT. “Reciprocal” anterior ST depression early in the course of transmural inferior myocardial infarction: an ECG finding of uncertain clinical significance. *Int J Cardiol* 1983;4:80–85.
 12. Zoghi M, Gürgün C, Yavuzgil O, et al. The angiographic correlation between ST segment depression in noninfarcted leads and the extent of coronary artery disease in patients with acute inferior myocardial infarction: a clue for multivessel disease. *Can J Cardiol* 2003;19:67–71.
 13. Forfar JC. Reciprocal ST segment changes in acute myocardial infarction: informative or incidental? *Q J Med* 1989;72:763–765.
 14. Gibelin P, Gilles B, Baudouy M, Guarino L, Morand P. Significance of ST segment depression in the precordial leads during the acute phase of inferior myocardial infarction. *Arch Mal Coeur Vaiss* 1985;78:1453–1461.
 15. Janse MJ, Cinca J, Moréna H, et al. The “border zone” in myocardial ischemia: an electrophysiological, metabolic, and histochemical correlation in the pig heart. *Circ Res* 1979;44:576–588.
 16. Holland RP, Arnsdorf MF. Solid angle theory and the electrocardiogram: physiologic and quantitative interpretations. *Prog Cardiovasc Dis* 1977;19:431–457.
 17. Holland RP, Brooks H, Lidl B. Spatial and nonspatial influences on the TQ-ST segment deflection of ischemia: theoretical and experimental analysis in the pig. *J Clin Invest* 1977;60:197–214.
 18. Wiegerinck RF, Gálvez-Monton C, Jorge E, Martínez R, Ricart E, Cinca J. Changes in QRS duration and R-wave amplitude in electrocardiogram leads with ST segment elevation differentiate epicardial and transmural myocardial injury. *Heart Rhythm* 2010;7:1667–1673.
 19. Cinca J, Figueras J, Tenorio L, et al. Time course and rate dependence of Q-T interval changes during uncomplicated acute transmural myocardial infarction in human beings. *Am J Cardiol* 1981;48:1023–1028.
 20. Sasaki K, Yotsukura M, Sakata K, Yoshino H, Ishikawa K. Relation of ST-segment changes in inferior leads during anterior wall acute myocardial infarction to length and occlusion site of the left anterior descending coronary artery. *Am J Cardiol* 2001;87:1340–1345.
 21. Ferguson DW, Pandian N, Kioschos JM, Marcus ML, White CW. Angiographic evidence that reciprocal ST-segment depression during acute myocardial infarction does not indicate remote ischemia: analysis of 23 patients. *Am J Cardiol* 1984;53:55–62.
 22. Lew AS, Hod H, Cercek B, Shan PK, Ganz W. Inferior ST segment changes during acute anterior myocardial infarction: a marker of the presence or absence of concomitant inferior wall ischemia. *J Am Coll Cardiol* 1987;10:519–526.
 23. Birnbaum Y, Sclarovsky S, Solodky A, et al. Prediction of the level of left anterior descending coronary artery obstruction during anterior wall acute myocardial infarction by the admission electrocardiogram. *Am J Cardiol* 1993;72:823–826.
 24. Quyyumi AA, Crake T, Rubens MB, Levy RD, Rickards AF, Fox KM. Importance of “reciprocal” electrocardiographic changes during occlusion of left anterior descending coronary artery: studies during percutaneous transluminal coronary angioplasty. *Lancet* 1986;327:347–350.
 25. Tabbalat RA, Haft JJ. Are reciprocal changes a consequence of “ischemia at a distance” or merely a benign electric phenomenon? A PTCA study. *Am Heart J* 1993;126:95–103.

AUTHORS . . .

Did you know . . .

You can find out who's citing your work?

Sign up for the free *CiteAlert* program and receive an e-mail when your work is cited.



Go to www.scopus.com, register, and sign up for the CiteAlert program.



2. **Artículo 2: Influence of the extent of coronary atherosclerotic disease on ST-segment changes induced by ST elevation myocardial infarction.** Francisco Javier Noriega, Miquel Vives-Borrás, Eduard Solé-González, Joan García-Picart, Dabit Arzamendi, Juan Cinca. Am J Cardiol. 2014;113:757-764.

Influence of the Extent of Coronary Atherosclerotic Disease on ST-Segment Changes Induced by ST Elevation Myocardial Infarction[☆]

Francisco J. Noriega, MD*, Miquel Vives-Borrás, MD, Eduard Solé-González, MD, Joan García-Picart, MD, Dabit Arzamendi, MD, and Juan Cinca, MD, PhD

The accuracy of the admission electrocardiogram (ECG) in predicting the site of acute coronary artery occlusion in patients with ST-segment elevation myocardial infarction (STEMI) and multivessel disease is not well known. This study aimed to assess whether the presence of multivessel coronary artery disease (CAD) modifies the artery-related ST-segment changes in patients with acute coronary artery occlusion. We reviewed the admission ECG, clinical records, and coronary angiography of 289 patients with STEMI caused by acute occlusion of left anterior descending (LAD; n = 140), right (n = 118), or left circumflex (LCx; n = 31) coronary arteries. All patients underwent primary percutaneous coronary reperfusion during the first 12 hours. The magnitude and distribution of artery-related ST-segment patterns were comparable in patients with single (n = 149) and multivessel (n = 140) CAD. Occlusion of proximal (n = 55) or mid-distal (n = 85) LAD artery induced ST-segment elevation in leads V₁ to V₅, but only the proximal occlusion induced reciprocal ST-segment depression in leads II, III, and aVF (p < 0.001). Proximal and mid-distal occlusion of right (n = 45 and 73, respectively) or LCx (n = 15 and 16) coronary artery always induced ST-segment elevation in leads II, III, and aVF and reciprocal ST-segment depression in leads V₂ and V₃. ST-segment elevation in lead V₆ > 0.1 mV predicted LCx artery occlusion. In conclusion, patients with STEMI with single or multivessel CAD have concordant artery-related ST-segment patterns on the admission ECG; in both groups, reciprocal ST-segment depression in LAD artery occlusion predicts a large infarct. Subendocardial ischemia at a distance is not a requisite for the genesis of reciprocal ST-segment changes. © 2014 The Authors. Published by Elsevier Inc. All rights reserved. (Am J Cardiol 2014;113:757–764)

The patterns of ST-segment shift are currently used to identify the infarct-related coronary artery and the level of the occlusion in patients with ST-segment elevation myocardial infarction (STEMI).^{1–4} In patients with multivessel coronary artery disease (CAD), the acute occlusion of a coronary artery may be associated with ischemia at a distance and this may modify the pattern of the ST-segment changes.⁵ However, the ability of the admission electrocardiogram (ECG) to predict the site of coronary occlusion in patients with STEMI with multiple CAD has not been

systematically analyzed. The purpose of this study was to compare the accuracy of the admission ECG in predicting the site of coronary occlusion in patients with STEMI with single and multivessel CAD.

Methods

We reviewed the clinical records of 373 consecutive patients with STEMI submitted to primary percutaneous coronary reperfusion in our institution from October 2009 to December 2010. The diagnosis of STEMI was based on typical chest pain lasting >30 minutes associated with ST-segment elevation of >0.1 mV in at least 2 consecutive electrocardiographic leads (0.2 mV for leads V₂ and V₃). Patients with ST-segment changes secondary to left bundle branch block (n = 19) or artificial ventricular paced rhythm (n = 5) were excluded.

Demographic, clinical, and echocardiographic data were extracted from the clinical records. The admission 12-lead ECG was recorded within the first 12 hours of the STEMI. Two independent investigators unaware of the clinical and angiographic data reviewed the electrocardiographic parameters. Positive and negative displacements of the ST segment were measured at the J-point level. Reciprocal ST-segment changes were defined as ST-segment depression of >0.1 mV in any electrocardiographic lead other than aVR (0.05 mV for V₂ and V₃).

Department of Cardiology, Hospital de la Santa Creu i Sant Pau, Institute of Biomedical Research (IIB Sant Pau), Universitat Autònoma de Barcelona, Barcelona, Spain. Manuscript received September 27, 2013; revised manuscript received and accepted November 12, 2013.

This study was supported by grant 080630-2007 from Fundació Marató TV3, Barcelona, Spain, grant RD06-0003-0000 from Redes Temáticas de Investigación Cooperativa en Salud del Instituto de Salud Carlos III (REDINSCOR), Madrid, Spain, and grant from Fondo Europeo de Desarrollo Regional (FEDER), Brussels, European Union.

[☆]This is an open-access article distributed under the terms of the Creative Commons Attribution-NonCommercial-No Derivative Works License, which permits non-commercial use, distribution, and reproduction in any medium, provided the original author and source are credited.

See page 764 for disclosure information.

*Corresponding author: Tel: (+34) 935565945; fax: (+34) 935565603.

E-mail address: fnoriega@santpau.cat (F.J. Noriega).

Table 1

Clinical and demographic characteristics of patients with acute occlusion of the left anterior descending (LAD), right, or left circumflex (LCx) coronary arteries

Variable	Coronary Artery Occluded					
	LAD (n = 140)		Right (n = 118)		LCx (n = 31)	
	Proximal (n = 55)	Mid-Distal (n = 85)	Proximal (n = 45)	Mid-Distal (n = 73)	Proximal (n = 15)	Mid-Distal (n = 16)
Age (yrs)	62.9 ± 16.3	61.9 ± 13.4	63.6 ± 11.9	61.5 ± 13.1	61.6 ± 15.1	57.3 ± 11.7
Men	44 (80)	65 (77)	37 (82)	60 (82)	12 (80)	13 (81)
Body mass index (kg/m ²)	27.7 ± 4.6	27.1 ± 3.5	26.8 ± 3.8	27.1 ± 4.0	28.5 ± 4.7	27.6 ± 5.5
Hypertension	30 (55)	50 (59)	23 (51)	37 (51)	9 (60)	8 (50)
Dyslipidemia	28 (51)	42 (49)	21 (47)	34 (47)	7 (47)	10 (63)
Diabetes mellitus	14 (26)	24 (28)	14 (31)	15 (21)	4 (27)	3 (19)
Current smoker	26 (47)	41 (48)	26 (58)	43 (59)	6 (40)	9 (56)
Previous STEMI	3 (6)	3 (4)	1 (2)	7 (10)	3 (20)	0
Previous non-STEMI	0	3 (4)	1 (2)	3 (4)	0	0
Killip class						
I	34 (62)	63 (74)	37 (82)	62 (85)	10 (67)	15 (94)
II	13 (24)	13 (15)	4 (9)	3 (4)	2 (13)	1 (6)
III	2 (4)	5 (6)	0	1 (1)	1 (7)	0
IV	6 (11)	4 (5)	4 (9)	7 (10)	2 (13)	0
Hemoglobin (g/dl)	14.0 ± 1.6	13.5 ± 1.8	13.3 ± 2.1	13.5 ± 1.7	12.8 ± 2.7	14.1 ± 2.2
Creatinine (mg/dl)	1.1 ± 0.5	1.0 ± 0.3	1.1 ± 0.6	1.0 ± 0.3	1.0 ± 0.4	1.1 ± 0.3

Data are presented as mean ± SD or n (%), as appropriate. p Value = NS.

Primary coronary angioplasty was performed in all patients within the first 4.3 ± 3.2 hours from the onset of symptoms. Angiographic findings were evaluated by 2 independent experienced observers blinded to the clinical and electrocardiographic data. The infarct-related artery was identified by total coronary artery occlusion or angiographic evidence of an intraluminal thrombus. Flow through the culprit lesion was graded using the Thrombolysis in Myocardial Infarction trial criteria.⁶ Any additional coronary stenosis of >70% was considered significant.⁷ We also assessed the presence of chronic total coronary artery occlusions, the distribution of collateral vessels, and the pattern of coronary dominance. Patients were divided into 3 groups according to the infarct-related artery: left anterior descending (LAD), right, and left circumflex (LCx). In each vessel we differentiated between the proximal and mid-distal location of the occlusion taking as a reference the first diagonal branch in the LAD group, the 1/2 distance to the acute margin of the heart in cases of the right coronary artery, and the first marginal branch in the LCx group.

Informed consent was obtained from each patient. The study protocol conforms to the ethical guidelines of the 1975 Declaration of Helsinki and was approved by the ethics committee of our institution.

Continuous variables are presented as the mean value ± SD and discrete variables as absolute value and percentage. Comparisons between continuous variables were assessed by the Student *t* test. Discrete variables were compared by the chi-square test. A *p* value <0.05 was considered statistically significant. Statistical analysis was performed using the software PASW statistics 19.0 (SPSS Inc, Chicago, Illinois).

Results

Among the 349 initially screened patients, we further excluded 19 with normal coronary angiography, 16 with unidentifiable infarct-related artery, and 25 in whom the infarct-

related artery was a secondary vessel (the diagonal branch of the LAD artery in 8 cases, the intermediate branch in 3, the posterior descending or posterolateral branches of the right coronary artery in 6, and the marginal branches of the LCx artery in 8). Thus, 289 patients were entered in the final analysis.

The demographic and clinical characteristics of patients with acute occlusion of the LAD, right, or LCx arteries were comparable (Table 1). However, patients with proximal LAD artery occlusion showed the highest peak values of cardiac biomarkers and the lowest left ventricular ejection fraction (Figure 1). Fourteen patients (4.8%) died during the hospital stay (cardiogenic shock in 13 patients and lethal arrhythmia in 1) and 11 of them presented with Killip class IV on admission. The in-hospital mortality distributed comparability among the 3 study groups with no further differences between patients with single or multivessel CAD.

Coronary angiography evidenced single-vessel disease in 149 patients (51%) and multiple-vessel disease in the remaining 140 patients (48%; 2-vessel in 98 patients [34%] and 3-vessel in 42 patients [14%]). The percentage of patients with multivessel CAD, chronic coronary occlusion, or coronary collaterals was homogeneously distributed among the 3 study groups (Table 2). A pattern of right coronary dominance was observed in most of the cases.

The first ECG was recorded within 183 ± 188 minutes from the onset of symptoms. The overall pattern and distribution of the ST-segment changes induced by acute proximal or mid-distal LAD artery occlusion was comparable in patients with single or multivessel CAD (Figure 2). However, the multivessel group presented subtle differences: lower ST-segment elevation in leads I (0.01 ± 0.07 vs 0.07 ± 0.12 mV, *p* = 0.03) and aVL (0.03 ± 0.08 vs 0.12 ± 0.17 mV, *p* = 0.01) and greater ST-segment elevation in lead V₁ (0.15 ± 0.13 vs 0.09 ± 0.10 mV, *p* = 0.05). The first septal branch was involved in 36 of the 55 patients of

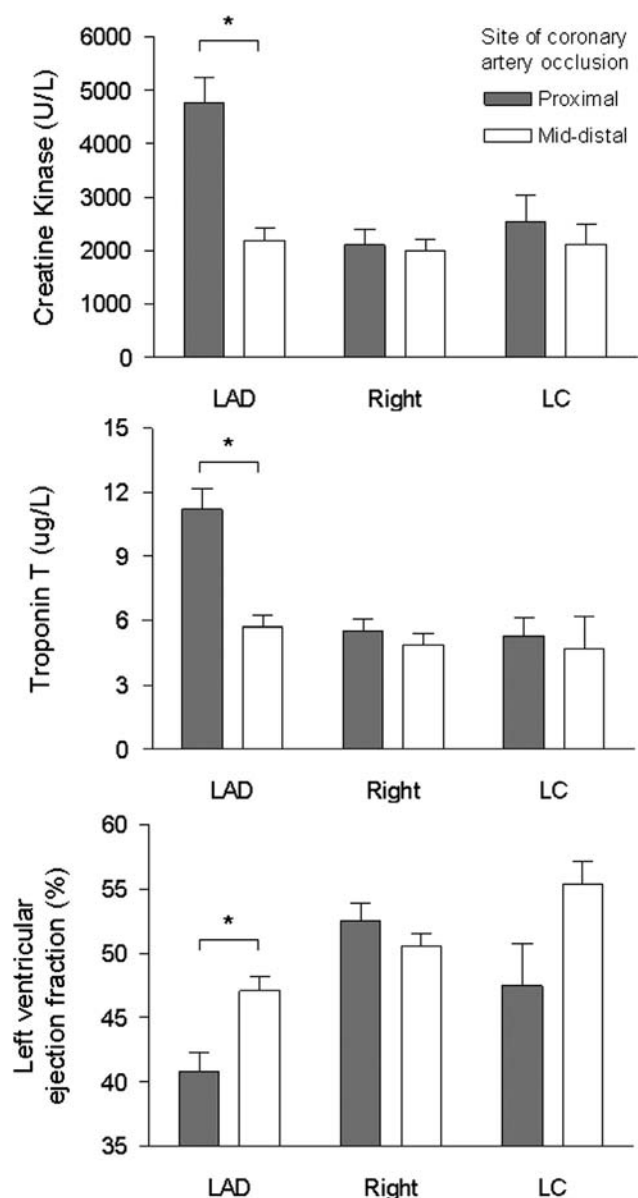


Figure 1. Cardiac biomarkers and left ventricular ejection fraction in patients with acute occlusion of LAD, right, or LCx coronary arteries. Bars indicate the mean ± SD of peak values of creatine kinase (upper panel), troponin T (middle panel), and left ventricular ejection fraction (lower panel) in patients with proximal or mid-distal occlusion of LAD, right, or LCx coronary arteries. *p Value <0.001.

the proximal LAD group. These patients showed greater ST-segment depression in leads III (-0.17 ± 0.16 vs -0.06 ± 0.10 mV, $p = 0.02$) and aVF (-0.13 ± 0.13 vs -0.06 ± 0.09 mV, $p = 0.04$).

Proximal and mid-distal right coronary artery occlusion induced ST-segment elevation in leads II, III, and aVF, and reciprocal ST-segment depression in leads I, aVL, and V₂ in patients with either single or multivessel CAD (Figure 3). In the latter cases, the reciprocal ST-segment changes extended to leads V₃ and V₄ ($p = 0.02$). The right ventricular branch was affected in 63 of the 118 patients with right coronary artery occlusion. The magnitude of ST-segment changes

Table 2
Angiographic findings in patients with acute occlusion of the left anterior descending (LAD), right, or left circumflex (LCx) coronary arteries

Variable	Coronary Artery Occluded					
	LAD (n = 140)		Right (n = 118)		LCx (n = 31)	
	Proximal (n = 55)	Mid-Distal (n = 85)	Proximal (n = 45)	Mid-Distal (n = 73)	Proximal (n = 15)	Mid-Distal (n = 16)
Number of coronary arteries narrowed						
1	26 (47)*	49 (58)*	22 (49)	38 (52)	6 (40)	8 (50)
>1	29 (53)*	36 (42)*	23 (51)	35 (48)	9 (60)	8 (50)
Collateral circulation	18 (33)	21 (25)	25 (56)	33 (45)	4 (27)	6 (38)
Chronic total occlusion	6 (11)	11 (13)	4 (9)	6 (8)	2 (13)	2 (13)
Right coronary dominance	48 (87)	73 (86)	43 (96)	73 (100)	9 (60)	12 (75)

Data are presented as n (%).
*p Value <0.05.

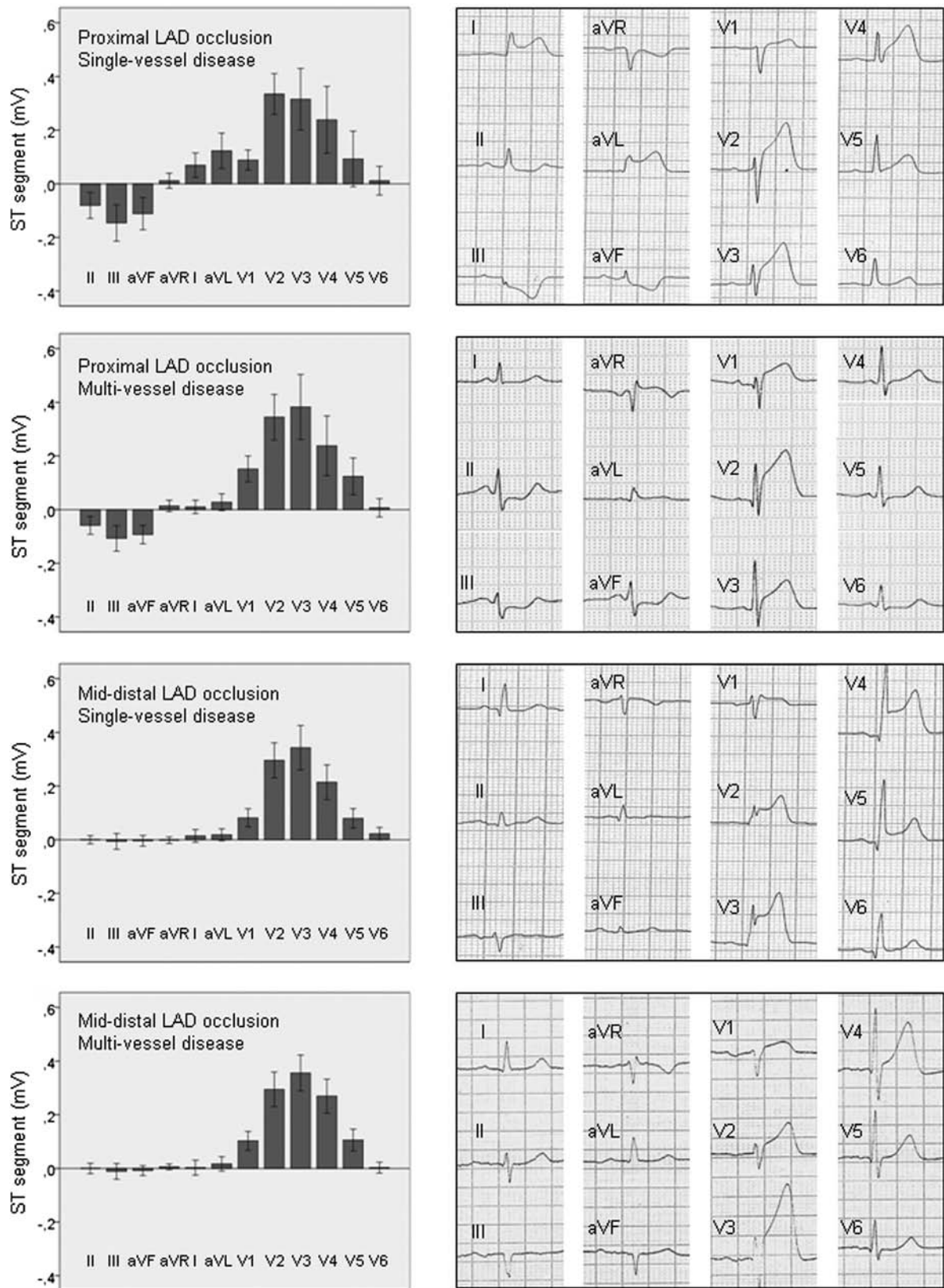


Figure 2. Electrocardiographic changes induced by acute occlusion of the LAD artery in patients with single and multivessel CAD. *Left panels* illustrate the mean \pm SD values (*bars*) of positive and negative ST-segment displacement in patients with proximal or mid-distal LAD artery occlusion and single or multivessel CAD. *Right panels* illustrate 12-lead ECG of representative patients in each study group.

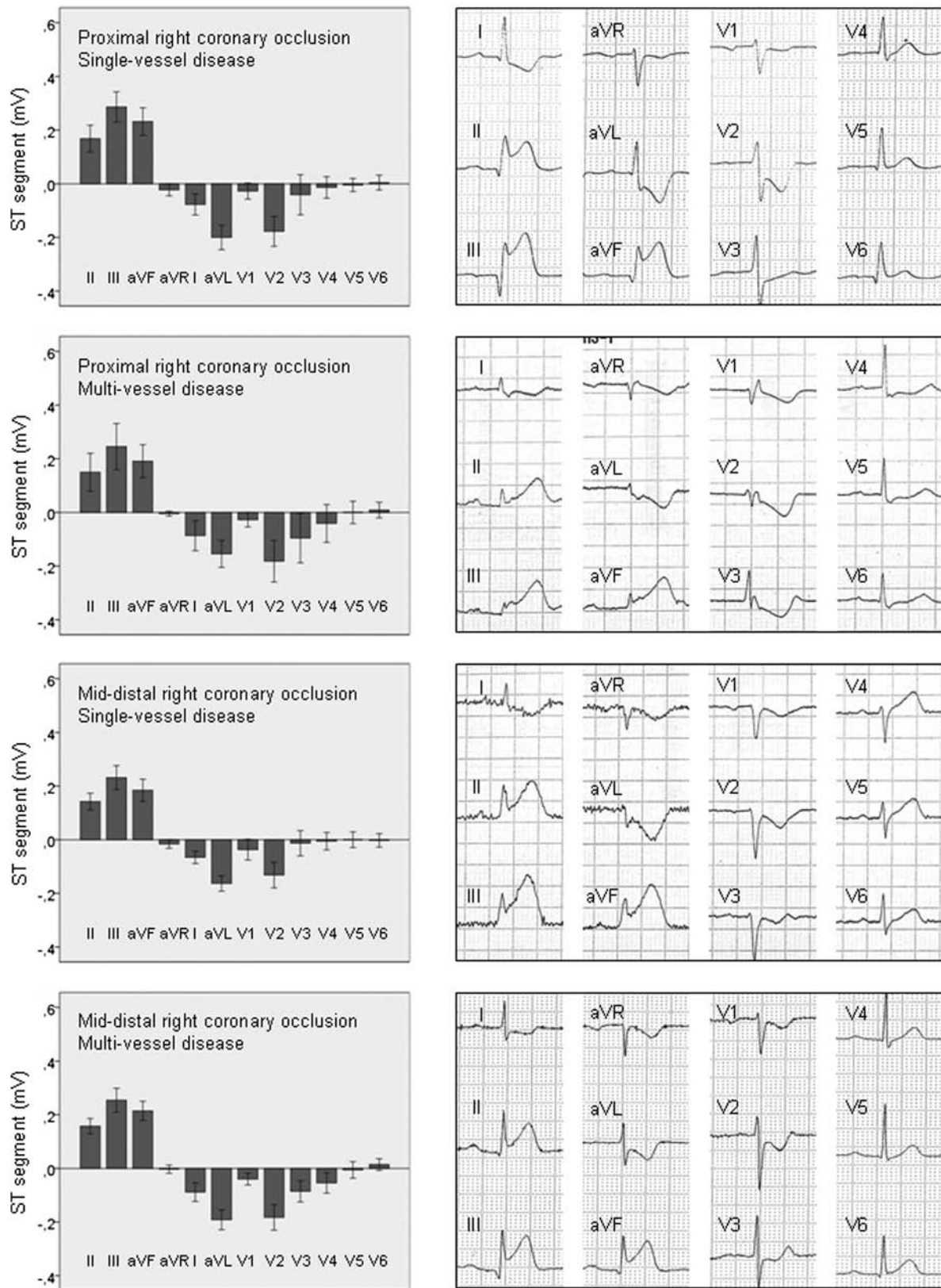


Figure 3. Electrocardiographic changes induced by acute occlusion of the right coronary artery in patients with single and multivessel CAD. *Left panels* illustrate the mean \pm SD values (*bars*) of positive and negative ST-segment displacement in patients with proximal or mid-distal right coronary artery occlusion and single or multivessel CAD. *Right panels* illustrate 12-lead ECG of representative patients in each study group.

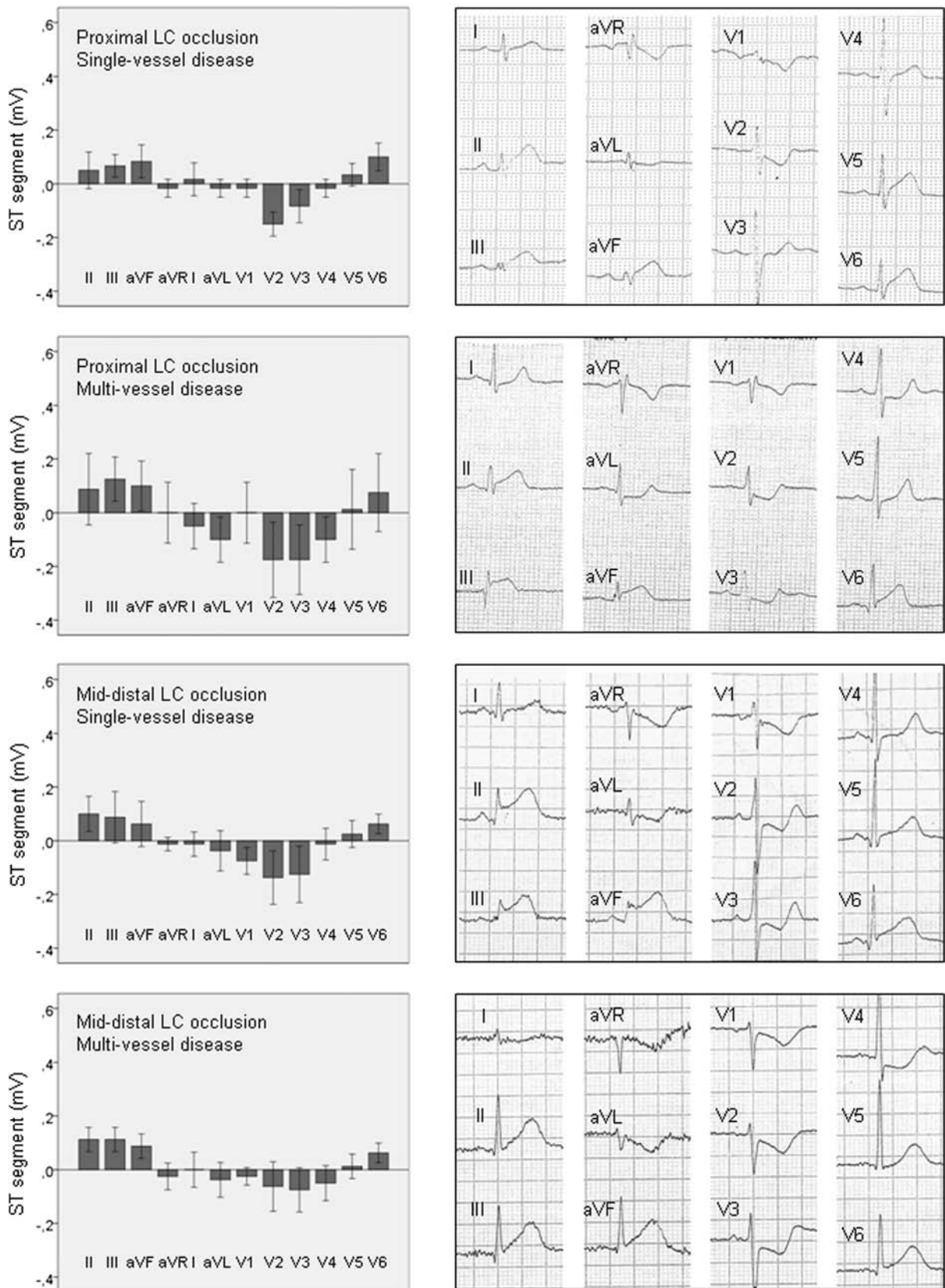


Figure 4. Electrocardiographic changes induced by acute occlusion of the LCx coronary artery in patients with single and multivessel CAD. *Left panels* illustrate the mean \pm SD values (*bars*) of positive and negative ST-segment displacement in patients with proximal or mid-distal LCx artery occlusion and single or multivessel CAD. *Right panels* illustrate 12-lead ECG of representative patients in each study group.

was comparable in patients with and without involvement of the right ventricular branch. Leads V₃R and V₄R were not routinely recorded.

Proximal and mid-distal LCx artery occlusion induced ST-segment elevation in leads II, III, aVF, and V₆ in patients with either single or multivessel CAD (Figure 4). These changes were associated in all instances with reciprocal ST-segment depression in leads V₂ and V₃. Of notice, in patients with multivessel CAD, the reciprocal ST-segment depression expanded to lead V₄. Compared with right coronary artery occlusion, LCx artery occlusion was associated with lower ST-segment elevation in leads II, III, and aVF ($p < 0.001$), lower reciprocal ST-segment depression in leads I and aVL ($p < 0.001$), and higher ST-segment elevation in lead V₆ ($p = 0.003$) in patients with either single or multivessel CAD (Figures 3 and 4). ST-segment elevation in lead V₆ predicted LCx artery occlusion with a sensitivity of 71% and a specificity of 83% in patients with single vessel disease and 63% and 82% in patients with multivessel CAD.

Discussion

This study shows that the pattern of combined elevation and depression of the ST segment that predicts the site of coronary occlusion in patients with acute STEMI is not essentially modified by the extent of the underlying atherosclerotic CAD, and only subtle differences were detected in some particular leads. Indeed, compared with patients with single CAD, those with multivessel impairment showed lesser ST-segment elevation in leads I and aVL after proximal LAD artery occlusion, and they presented reciprocal ST-segment depression in lead V₄ after right or LCx artery occlusion. Although we cannot establish the mechanism of these differences, patients with STEMI with multivessel CAD may develop additional subendocardial ischemia at a distance from the infarction and this could magnify the reciprocal ST-segment changes and also counteract the ST-segment elevation in the opposite infarcted region. Indeed, patients with STEMI with $>85\%$ stenosis of coronary vessels opposed to the infarct-related artery, and thus prone to develop subendocardial ischemia at a distance, showed a more marked reciprocal ST-segment depression pattern.⁸ Likewise, transmural ischemia in opposite regions may attenuate the reciprocal ST-segment changes.^{3,9}

The presence of reciprocal ST-segment depression in electrocardiographic leads overlying nonischemic regions was reported in early studies on acute myocardial ischemia.^{10–13} Our study further shows that the reciprocal ST-segment pattern is present in all patients with STEMI with right or LCx artery occlusion independently of the level of vessel occlusion. Moreover, in patients with LAD artery occlusion, the reciprocal changes were only observed when the occlusion affected the proximal but not the mid-distal segment. Thus, the presence of reciprocal ST-segment depression in patients with LAD artery occlusion predicts extensive infarction as has been previously appreciated in the early^{14,15} and subacute phases^{2,16} of STEMI.

Patients with right or LCx artery occlusion can indistinctly present ST-segment elevation in leads II, III, and aVF. Thus, several differential electrocardiographic criteria have been reported: (1) ST-segment elevation in lead III $>$ lead II

suggesting right coronary artery occlusion with a sensitivity of 88% and specificity of 69%⁴; (2) ST-segment depression in lead I suggesting right coronary artery occlusion, with a 92% sensitivity and 77% specificity⁴; and (3) A ratio of ST-segment depression in leads V₁ to V₃/ST-segment elevation in leads II, III, aVF⁴ or V₃/III¹ < 1 , implying right coronary artery occlusion, and > 1 suggesting LCx artery occlusion with 94% sensitivity and 61% specificity.⁴ In our patients, we found lower predictive values: 72% sensitivity and 73% specificity for criteria 1, 54% and 73% for criteria 2, and 88% and 57% for criteria 3, respectively. As a novel finding, we observed that ST-segment elevation > 0.1 mV in lead V₆ suggested LCx artery occlusion with 71% sensitivity and 83% specificity.

Elevation of the ST segment in STEMI is caused by injury currents coursing between the normal and the ischemic myocardial regions.^{17,18} These currents flow during the resting phase and during phase II of action potential, and they give rise, respectively, to TQ-segment depression and true ST-segment elevation in direct-current electrical recordings.¹⁹ Because the electrocardiographic recorders use alternating current-coupled amplifiers, the TQ and ST-segment shifts cannot be differentiated and both emerge as global ST-segment elevation in the conventional ECG.

The mechanism underlying the reciprocal ST-segment depression in patients with STEMI is more complex. After the early description by Wolferth et al,¹¹ 2 mechanisms have been considered: (1) mirror projection of the ST-segment elevation at a distance from the infarcted region^{20–22} and (2) true ST-segment deviation caused by additional subendocardial ischemia at a distance from the infarction.^{23–25} By taking simultaneous recordings of the conventional ECG and left ventricular local intramural electrograms in pigs with acute coronary occlusion free of distant subendocardial ischemia,²⁶ we found that the reciprocal ST-segment depression was due to the conventional design of the electrocardiographic lead system and not the transmission of the ST-segment potential from the ischemic to the distant normal myocardium. This observation was in accordance with the mathematical predictions of the solid angle theory.^{27,28}

In the absence of ischemia at a distance, the time course of the ST-segment elevation and the reciprocal ST-segment depression followed a parallel trend, as we observed during the first 5 minutes of coronary occlusion-reperfusion in the porcine model.²⁶ However, because the magnitude of the ST-segment elevation was usually greater than that of reciprocal ST-segment depression, it is conceivable that during the spontaneous recovery of the ST segment in the subacute phase of infarction, the reciprocal ST-segment changes vanished sooner. Therefore, analysis of the ECG obtained later than 12 hours of infarction would hamper the assessment of reciprocal ST-segment patterns.

In our study, we could not directly confirm the presence of added subendocardial ischemia at a distance from the infarction because this is not routinely evaluated in the acute management of patients with STEMI. However, our patients might likely develop added subendocardial ischemia because we established a coronary stenosis cut-off value of 70%, which is an accepted angiographic risk threshold for ischemia.⁷

Like in other clinical series, the number of patients with acute LCx artery occlusion in our study was relatively low.

Moreover, we did not include patients with LCx artery occlusion presenting exclusively with ST-segment depression because the purpose of the study was to address the STEMI condition. Our data suggest that ST-segment elevation in V₆ is an electrocardiographic criteria for LCx artery occlusion, although the strength of this finding would require further assessment in studies with larger number of patients.

Disclosures

The authors have no conflicts of interest to disclose.

- Kosuge M, Kimura K, Ishikawa T, Hongo Y, Mochida Y, Sugiyama M, Tochikubo O. New electrocardiographic criteria for predicting the site of coronary artery occlusion in inferior wall acute myocardial infarction. *Am J Cardiol* 1998;82:1318–1322.
- Engelen DJ, Gorgels AP, Cheriex EC, De Muinck ED, Ophuis AJ, Dassen WR, Vainer J, Van Ommen VG, Wellens HJ. Value of the electrocardiogram in localizing the occlusion site in the left anterior descending coronary artery in acute anterior myocardial infarction. *J Am Coll Cardiol* 1999;34:389–395.
- Sasaki K, Yotsukura M, Sakata K, Yoshino H, Ishikawa K. Relation of ST-segment changes in inferior leads during anterior wall acute myocardial infarction to length and occlusion site of the left anterior descending coronary artery. *Am J Cardiol* 2001;87:1340–1345.
- Fiol M, Cygankiewicz I, Carrillo A, Bayés-Genis A, Santoyo O, Gómez A, Bethencourt A, Bayés de Luna A. Value of electrocardiographic algorithm based on “ups and downs” of ST in assessment of a culprit artery in evolving inferior wall acute myocardial infarction. *Am J Cardiol* 2004;94:709–714.
- Mirvis DM. Physiologic bases for anterior ST segment depression in patients with acute inferior wall myocardial infarction. *Am Heart J* 1988;116:1308–1322.
- TIMI Study Group. The Thrombolysis In Myocardial Infarction (TIMI) trial. Phase I findings. *N Engl J Med* 1985;312:932–936.
- Levine GN, Bates ER, Blankenship JC, Bailey SR, Bittl JA, Cercek B, Chambers CE, Ellis SG, Guyton RA, Hollenberg SM, Khot UN, Lange RA, Mauri L, Mehran R, Moussa ID, Mukherjee D, Nallamothu BK, Ting HH. 2011 ACCF/AHA/SCAI Guideline for Percutaneous Coronary Intervention. A report of the American College of Cardiology Foundation/American Heart Association Task Force on Practice Guidelines and the Society for Cardiovascular Angiography and Interventions. *J Am Coll Cardiol* 2011;58:e44–122.
- Kyriakidis M, Antonopoulos A, Barbetseas J, Aspiotis N, Georgiakodis F, Sfikakis P, Toutouzas P. Correlation of reciprocal ST-segment depression after acute myocardial infarction with coronary angiographic findings. *Int J Cardiol* 1992;36:163–168.
- Lew AS, Hod H, Cercek B, Shah PK, Ganz W. Inferior ST segment changes during acute anterior myocardial infarction: a marker of the presence or absence of concomitant inferior wall ischemia. *J Am Coll Cardiol* 1987;10:519–526.
- Pardee HE. An electrocardiographic sign of coronary artery obstruction. *Arch Intern Med* 1920;26:244–257.
- Wolferth CC, Bellet S, Livezey MM, Murphy FD. Negative displacement of the RS-T segment in the electrocardiogram and its relationships to positive displacement: an experimental study. *Am Heart J* 1945;29:220–245.
- Alzamora-Castro V, Battilana G, Abugattas R. The electrical manifestations observed in damaged or injured cardiac muscle. An experimental study. *Am Heart J* 1957;54:254–263.
- Camara EJ, Chandra N, Ouyang P, Gottlieb SH, Shapiro EP. Reciprocal ST change in acute myocardial infarction: assessment by electrocardiography and echocardiography. *J Am Coll Cardiol* 1983;2:251–257.
- Tamura A, Kataoka H, Mikuriya I, Nasu M. Inferior ST segment depression as a useful marker for identifying proximal left anterior descending artery occlusion during acute anterior myocardial infarction. *Eur Heart J* 1995;16:1795–1799.
- Fiol M, Carrillo A, Cygankiewicz I, Velasco J, Riera M, Bayés-Genis A, Gómez A, Peral V, Bethencourt A, Goldwasser D, Molina F, Bayés de Luna A. A new electrocardiographic algorithm to locate the occlusion in left anterior descending coronary artery. *Clin Cardiol* 2009;32:E1–E6.
- Birbaum Y, Solodky A, Herz I, Kusniec J, Rechavia E, Sulkes J, Sklarovsky S. Implications of inferior ST-segment depression in acute anterior myocardial infarction: electrocardiographic and angiographic correlation. *Am Heart J* 1994;127:1467–1473.
- Janse MJ, Cinca J, Moréna H, Fiolet JW, Kléber AG, de Vries GP, Becker AE, Durrer D. The “border zone” in myocardial ischemia. An electrophysiological, metabolic, and histochemical correlation in the pig heart. *Circ Res* 1979;44:576–588.
- Cinca J, Janse MJ, Moréna H, Candell J, Valle V, Durrer D. Mechanism and time course of the early electrical changes during acute coronary artery occlusion. An attempt to correlate the early ECG changes in man to the cellular electrophysiology in the pig. *Chest* 1980;77:499–505.
- Kléber AG, Janse MJ, Van Capelle FJ, Durrer D. Mechanism and time course of S-T and T-Q segment changes during acute regional myocardial ischemia in the pig heart determined by extracellular and intracellular recordings. *Circ Res* 1978;42:603–613.
- Little WC, Rogers EW, Sodums MT. Mechanism of anterior ST segment depression during acute inferior myocardial infarction. Observations during coronary thrombolysis. *Ann Intern Med* 1984;100:226–229.
- Quyyumi AA, Crake T, Rubens MB, Levy RD, Rickards AF, Fox KM. Importance of “reciprocal” electrocardiographic changes during occlusion of left anterior descending coronary artery. Studies during percutaneous transluminal coronary angioplasty. *Lancet* 1986;327:347–350.
- Tabbalat RA, Haft JJ. Are reciprocal changes a consequence of “ischemia at a distance” or merely a benign electric phenomenon? A PTCA study. *Am Heart J* 1993;126:95–103.
- Brymer JF, Khaja F, Marzilli M, Goldstein S. “Ischemia at a distance” during intermittent coronary artery occlusion: a coronary anatomic explanation. *J Am Coll Cardiol* 1985;6:41–45.
- Forfar JC. Reciprocal ST segment changes in acute myocardial infarction; informative or incidental? *Q J Med* 1989;72:763–765.
- Zoghi M, Gürgün C, Yavuzgil O, Türkoglu I, Kültürsay H, Akilli A, Akin M, Türkoglu C. The angiographic correlation between ST segment depression in noninfarcted leads and the extent of coronary artery disease in patients with acute inferior myocardial infarction: a clue for multivessel disease. *Can J Cardiol* 2003;19:67–71.
- Noriega FJ, Jorge E, Arzamendi D, Cinca J. Mechanism and diagnostic potential of reciprocal ECG changes induced by acute coronary artery occlusion in pigs. *Heart Rhythm* 2013;10:883–890.
- Holland RP, Arnsdorf MF. Solid angle theory and the electrocardiogram. Physiologic and quantitative interpretations. *Prog Cardiovasc Dis* 1977;19:431–457.
- Holland RP, Brooks H, Lidl B. Spatial and nonspatial influences on the TQ-ST segment deflection of ischemia. Theoretical and experimental analysis in the pig. *J Clin Invest* 1977;60:197–214.

3. **Artículo 3: ST-segment deviation behaviour during acute myocardial ischemia in opposite ventricular regions: Observations in the intact and perfused heart.** Juan Cinca, Francisco Javier Noriega, Esther Jorge, Jesús Álvarez-García, Gerard Amorós, Dabit Arzamendi. Heart Rhythm. 2014;11:2084-2091.

ST-segment deviation behavior during acute myocardial ischemia in opposite ventricular regions: Observations in the intact and perfused heart

Juan Cinca, MD, PhD, Francisco Javier Noriega, MD, Esther Jorge, DVM, PhD, Jesús Alvarez-García, MD, Gerard Amorós, MSc, Dabir Arzamendi, MD

From the Department of Cardiology, Hospital de la Santa Creu i Sant Pau, Institute of Biomedical Research IIB Sant Pau, Universitat Autònoma de Barcelona, Barcelona, Spain.

BACKGROUND Acute myocardial ischemia in opposite regions may attenuate ST-segment changes, but whether this effect is expressed differently in extracardiac compared to direct intramyocardial recordings is not well known.

OBJECTIVE The purpose of this study was to characterize ST-segment changes induced by opposite ischemic regions in intact and isolated perfused pig hearts.

METHODS Left anterior descending (LAD) and right coronary arteries (RCA) were occluded in 7 closed chest pigs and in 5 isolated pig hearts. ST-segment changes were analyzed in 12-lead ECG and in local extracellular electrograms.

RESULTS Isolated LAD or RCA occlusion induced maximal ST-segment elevation in leads V_4 (0.84 ± 0.30 mV, $P = .003$) and III (0.16 ± 0.11 mV, $P = .04$), respectively. RCA occlusion also induced reciprocal ST-segment depression maximal in lead V_4 (-0.40 ± 0.16 mV, $P = .005$). Simultaneous LAD and RCA occlusion reduced ST-segment elevation by about 60% and blunted reciprocal ST-segment changes. Reperfusion of 1 of the 2 occluded arteries induced immediate regional reversion of ST-segment elevation with

concurrent beat-to-beat re-elevation in the opposite ischemic region and reappearance of reciprocal ST-segment changes. In the isolated heart, single LAD or RCA ligation induced regional transmural ST-segment elevation that was maximal in endocardial electrograms with no appreciable reciprocal ST-segment depression. Simultaneous LAD and RCA ligation reduced ST-segment elevation by about 30% with no appreciable re-elevation after 1-vessel selective reperfusion.

CONCLUSION Acute myocardial ischemia in opposite ventricular regions attenuated ST-segment elevation and blunted reciprocal depression in conventional ECG leads but not in direct local myocardial electrograms.

KEYWORDS Myocardial ischemia; ST-segment cancellation; Double coronary occlusion; *In situ* heart; Isolated heart

ABBREVIATIONS ECG = electrocardiographic; LAD = left anterior descending; LV = left ventricle; RCA = right coronary artery

(Heart Rhythm 2014;11:2084–2091) © 2014 Heart Rhythm Society. All rights reserved.

Introduction

Simultaneous ischemia in opposite left ventricular (LV) regions may occur clinically, but the resultant electrocardiographic (ECG) changes have not been systematically studied and are not well understood.

Patients with significant multivessel coronary artery disease may present with ischemia in opposite LV regions during exercise, which may counterbalance ST-segment changes and result in falsely negative exercise ECG test.¹ In the literature, ST-segment changes have been described in

patients with simultaneous occlusion of the left anterior descending (LAD) and right coronary arteries (RCA).^{2–5} It also has been shown that in patients with a single distal occlusion of the LAD, elevation of the ST segment can be present in both inferior (II, III, aVF) and precordial leads (V_2 – V_5) mimicking a pattern suggesting simultaneous LAD and RCA occlusion.^{6,7}

Ischemic ST-segment shifts (both elevation and reciprocal depression) that are induced by simultaneous myocardial ischemia in opposite regions have not been systematically analyzed. Moreover, it is not known whether cancellation of ST-segment changes truly occurs in the local cardiac recordings or it is only detected by conventional ECG leads as a result of spatial summation of the injury currents of different direction generated by the opposite ischemic regions.

In this study, we performed single and combined occlusion of the LAD and RCA in *in situ* and isolated perfused pig heart in order to characterize the patterns of ST-segment

This study was supported by grants from Fundació Marató TV3 (grant no. 080630-2007), Redes Temáticas de Investigación Cooperativa en Salud del Instituto de Salud Carlos III (REDINSCOR, grant no. RD06-0003-0000), and Fondo Europeo de Desarrollo Regional (FEDER). **Address reprint requests and correspondence:** Dr. Juan Cinca, Department of Cardiology, Hospital de la Santa Creu i Sant Pau, St. Antoni M. Claret, 167, 08025, Barcelona, Spain. E-mail address: jcinca@santpau.cat.

cancellation induced by opposite ischemic regions and to determine whether this counteracting effect is detected differently in the intact and in the isolated perfused heart.

Methods

Study population

Twelve female domestic swine (Landrace–Large White cross) weighing 40 kg were sedated with azaperone (8 mg/kg intramuscular, Stressnil; Esteve Farma SA, Barcelona, Spain) and anesthetized with sodium thiopental (10 mg/kg intravenous, Pentothal; B. Braun Medical SA, Barcelona, Spain). They were intubated and mechanically ventilated with a mixture of oxygen and 2% isoflurane to maintain general anesthesia. Fentanyl (0.005 mg/kg intravenous, Fentanest; Kern Pharma SL, Barcelona, Spain) and atracurium besylate (1 mg/kg intravenous, Tracrium; GlaxoSmithKline SA, Madrid, Spain) were administered during the procedure for analgesia and muscular relaxation, respectively.

The study protocol was approved by the ethics and animal welfare committee of our institution, according to the regulations for treatment of animals established by the *Guide for the Care and Use of Laboratory Animals* published by the U.S. National Institutes of Health (NIH Publication No. 85-23, revised 1996).

Experimental series

In situ heart

Seven pigs were included in the series. All animals were free of significant atherosclerotic coronary artery disease as determined by coronary angiography.

Coronary artery occlusion. Acute transmural myocardial ischemia was induced by percutaneous coronary catheter balloon occlusion. Both femoral arteries were catheterized, and two 7Fr introducers were used to insert 6Fr guide catheters (Merit Medical Europe, Maastricht, The Netherlands). Under fluoroscopic control, the catheters were advanced to the ostium of the left and right coronary arteries. Then, 2 coronary catheters with a 3-mm × 15-mm balloon (Maverick, Boston, MA) were positioned at the mid-segment of the LAD, distal to the first septal and first diagonal branch, and mid-segment of the RCA. The position of the catheter balloon was verified by coronary angiography. Sodium heparin (70 IU/kg, bolus injection) was given to prevent thrombus formation during the procedure. Coronary occlusion was induced by transient (5-minute) inflation of the balloon at 12 atm.

Conventional 12-lead ECG. The 12-lead ECG was continuously recorded and stored on a hard disk of a multi-channel recording system (Prucka Engineering Inc, Houston, TX). Because of species anatomy, the precordial leads were placed 1 intercostal space above that used in current clinical ECG. In each ECG recording, we measured the magnitude of the ST-segment deviation at the J-point level.

Study protocol. Five of the 7 pigs underwent single occlusion of the LAD and RCA for 5 minutes spaced by 10 minutes of coronary reperfusion. Thereafter, both coronary arteries were occluded simultaneously for 5 minutes, followed by selective release of the LAD or the RCA. In the remaining 2 pigs of this series of 7, a double LAD and RCA was performed as the first intervention to assess whether the trend of ST-segment changes during selective reperfusion were comparable in pigs with and those without previous ischemia. The ECG was recorded at baseline and continuously during each ischemia–reperfusion cycle. Pigs that presented with ventricular fibrillation were excluded from the study to avoid potential confounding effects of electrical defibrillation on the ST segment.

Isolated Langendorff perfused heart

This model was used to assess whether the ST-segment changes induced by opposite ischemia were detected differently in the peripheral ECG and in direct local intramural electrograms. A mid-sternotomy was performed to expose the heart. After administration of intravenous sodium heparin (70 IU/kg, bolus injection), 1000 mL of blood was collected. Then, the heart was removed and rapidly immersed in cold Tyrode's solution. The aorta was cannulated and connected to a Langendorff perfusion setup filled with the extracted blood. The circulating blood was oxygenated by a mixture of 95% O₂ and 5% CO₂ using a clinical extracorporeal oxygenator (Palex SA, Barcelona, Spain), and the temperature was maintained around 37°C. Likewise, the perfusion flow was maintained at a mean pressure of about 70 mm Hg. Samples of the perfusate were extracted to keep blood gases and pH at normal values (pO₂ > 90%, pH ≈ 7.45). A direct current electrical shock of 15 J was applied to defibrillate the heart.

Coronary artery occlusion. The LAD was dissected at its middle segment after the origin of the first diagonal branch and looped with a Prolene 3/0 snare. The RCA was also dissected at its middle segment, and a Prolene snare was placed around it. The 2 ends of the suture were threaded through a smooth plastic tube, and the artery was acutely occluded by sliding the tubing over the suture and clamping it with a small hemostat clamp. Reperfusion was accomplished by releasing the ligature.

Transmural local electrograms. Transmural needle electrodes containing 3 electrodes spaced 3 mm apart were inserted in the wall of the left ventricle in a row extending from the anterior to the posterior region, spaced about 2–3 cm. The reference electrode was placed in the aortic root. Signals were recorded using a BioSemi Mark-V acquisition system (Amsterdam, The Netherlands). A waiting period of 60 minutes was followed to allow recovery of the injury caused during insertion of the electrodes. Local electrograms that did not recover were excluded from the study. Offline analysis of all recorded electrograms was done using a

custom-made data analysis program. In each recording, we measured the magnitude of the ST-segment deviation at the J-point level.

Study protocol. Five animals were included in the series. All hearts underwent single occlusion of the LAD and RCA for 5 minutes spaced by 10 minutes of reperfusion. Thereafter, both coronary arteries were occluded simultaneously for 5 minutes, followed by sequential release of the LAD (2 cases) or the RCA (2 other hearts). Local electrograms were recorded at baseline and during each ischemia-reperfusion sequence. Hearts that presented with ventricular fibrillation during the coronary occlusion-reperfusion episodes were excluded from the study to avoid potential confounding effects of electrical defibrillation on the ST segment.

Data analysis

Data are given as mean ± SD. Statistical significance of the ST-segment changes from baseline to 5 minutes of coronary occlusion were assessed by either paired samples *t* test or 1-way repeated measures analysis of variance using PASW Statistics 18.0 software (SPSS Inc, Chicago, IL). *P* < .05 was considered significant.

Results

Intact heart

Seven pigs were included in the study. In 5 cases, the middle segments of the LAD and RCA were separately occluded for 5 minutes spaced by 10 minutes of reperfusion; thereafter the LAD and RCA were simultaneously reoccluded. As shown in **Figure 1**, mid-LAD occlusion induced ST-segment elevation in leads V₁-V₆ (maximal in lead V₄: 0.84 ±

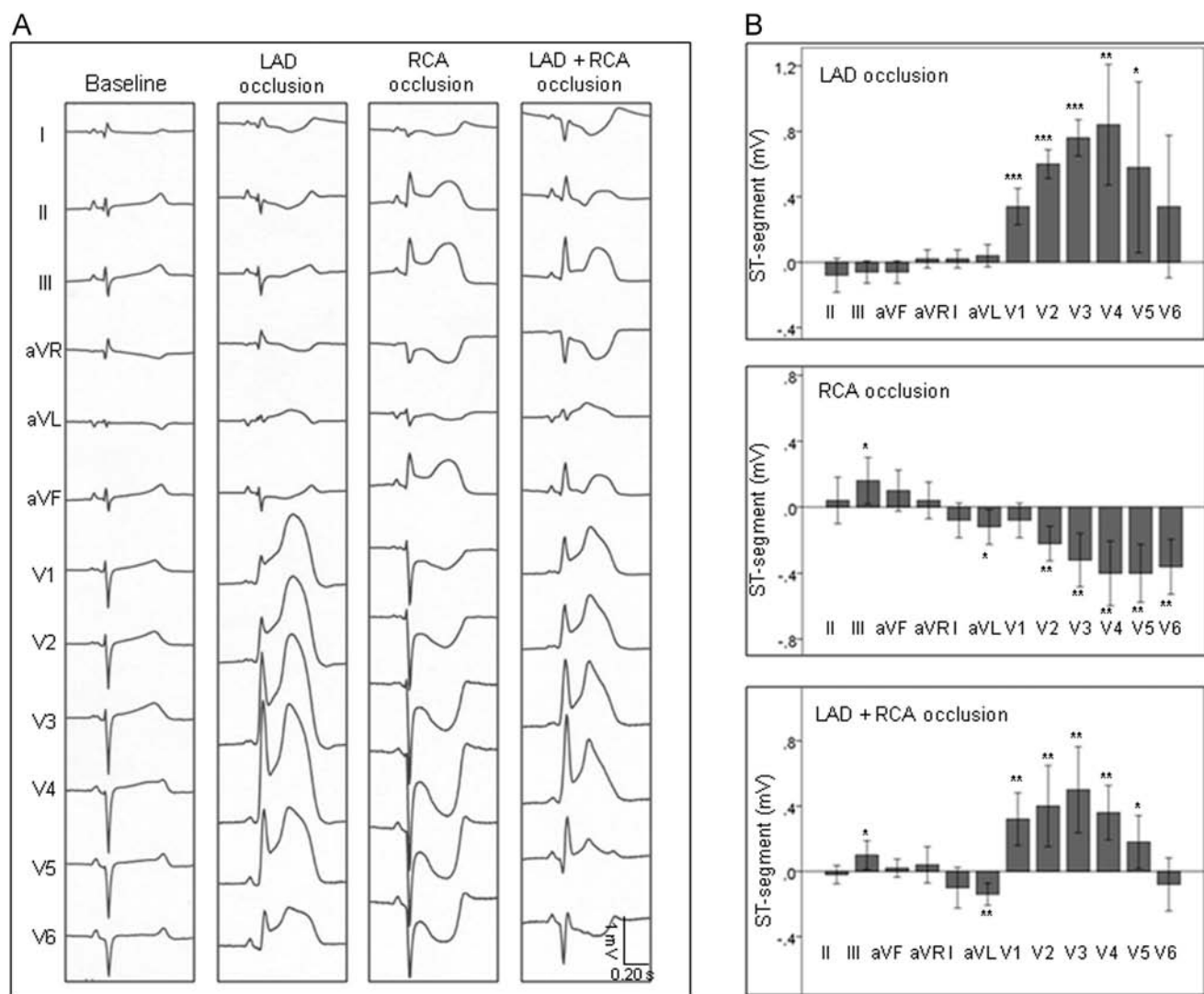


Figure 1 ST-segment changes induced by single and combined occlusion of the left anterior descending (LAD) and right coronary arteries (RCA) in anesthetized pigs. **A:** Twelve-lead ECG recorded in a pig at baseline and after 5 minutes of single and combined LAD and RCA ligation, all spaced by 10 minutes of reperfusion recovery. **B:** ST-segment displacement (mean ± SD [bars]) in the 12-lead ECG in 5 pigs submitted to single and combined LAD and RCA occlusion separated by 10 minutes of reperfusion recovery. Double coronary occlusion attenuated ST-segment elevation and blunted reciprocal ST-segment changes. Asterisks indicate level of statistical significance (**P* < .05; ***P* < .01; ****P* < .001).

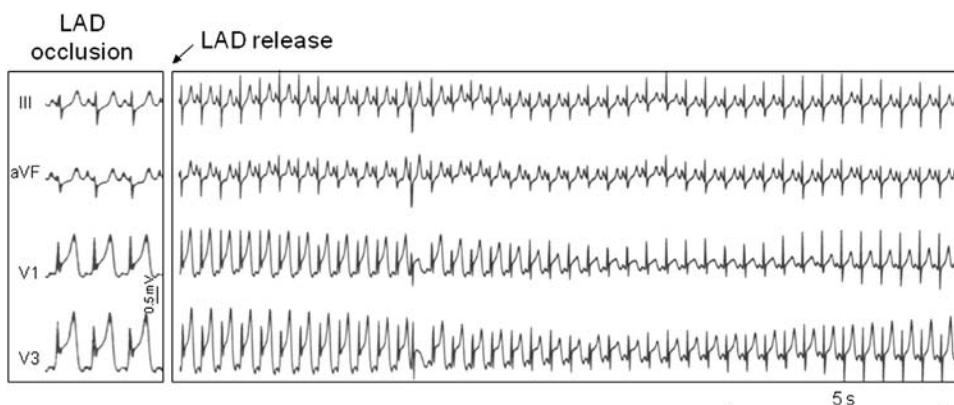


Figure 2 Effects of coronary reperfusion on ischemic ECG changes induced by 5 minutes of left anterior descending artery (LAD) occlusion in an anesthetized pig. ECG leads III, aVF, V₁, and V₃ are shown at 5 minutes of LAD occlusion (**left**) and continuously after release of the LAD (**right**). Coronary reperfusion induced rapid normalization of ST-segment elevation with transient appearance of peaked T waves. Time scale is indicated in seconds.

0.30 mV, $P = .003$) and slight nonsignificant reciprocal ST-segment depression in leads II, III, and aVF. Occlusion of the mid-RCA elicited ST-segment elevation in leads II, III, and aVF (maximal in lead III: 0.16 ± 0.11 mV, $P = .04$) and reciprocal ST-segment depression in leads I, aVL, and V₁–V₆ (maximal in lead V₄: -0.40 ± 0.16 mV, $P = .005$). Coronary reperfusion after a single 5-minute coronary ligature elicited fast normalization of ST-segment elevation and transient appearance of peaked T waves (illustrative example shown in **Figure 2**). Simultaneous LAD and RCA occlusion was followed by a reduction of approximately 60% in the magnitude of ST-segment elevation attained during the previous single-vessel occlusion. Moreover, double coronary occlusion abolished the reciprocal ST-segment depression that was recorded in leads II, III, and

aVF or in leads V₁–V₅ during separate LAD and RCA occlusion, respectively. Of note, leads I, aVL, and V₆ continued to show reciprocal ST-segment depression (maximal in lead aVL: -0.14 ± 0.05 mV, $P = .005$). A typical example of single and combined LAD and RCA occlusion is shown in **Figure 1A**. Of interest in the LAD occlusion is, in addition to the ST-segment changes, the development of R waves in the precordial leads suggestive of delay in conduction to the epicardial layer. These R waves persisted in case of simultaneous LAD and RCA occlusion. Selective release of either of the 2 occluded coronary arteries induced immediate regional reversion of the ST-segment elevation associated with concurrent beat-to-beat re-elevation of the ST segment in the opposite ischemic region and reappearance of reciprocal ST-segment changes. The magnitude of

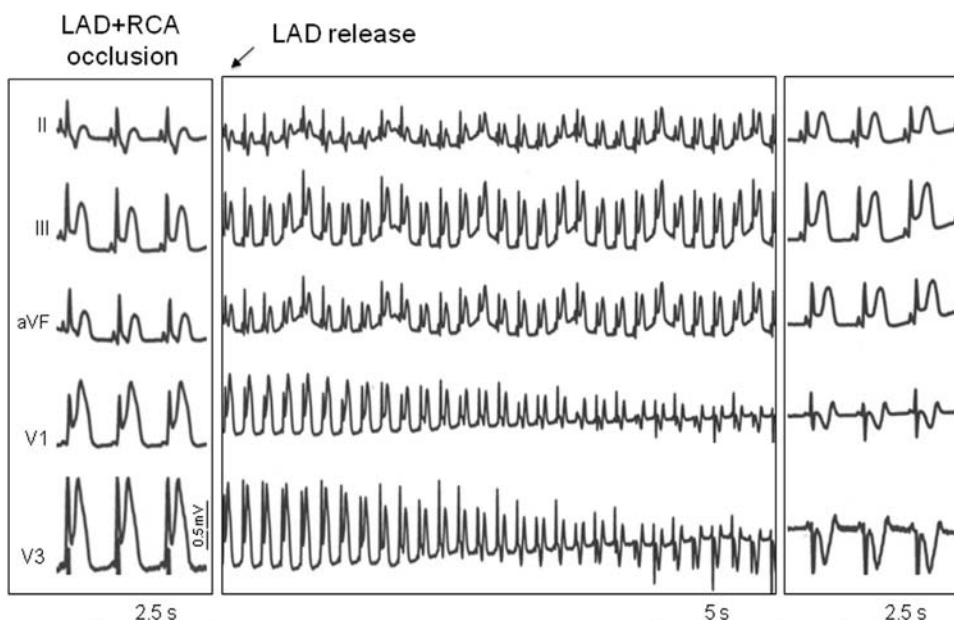


Figure 3 Effects of selective coronary reperfusion on ischemic ECG changes induced by 5 minutes of double left anterior descending (LAD) and right coronary arteries (RCA) occlusion in an anesthetized pig. ECG leads II, III, aVF, V₁, and V₃ are shown at 5 minutes of double LAD and RCA occlusion (**left**) and during release of the LAD while the RCA remained occluded (**middle, right**). Release of the LAD induced fast normalization of ST-segment elevation in leads V₁ and V₃ leading to reciprocal ST-segment inversion associated with concurrent beat-to-beat ST-segment re-elevation in leads II, III, and aVF. Time scale is indicated in seconds.

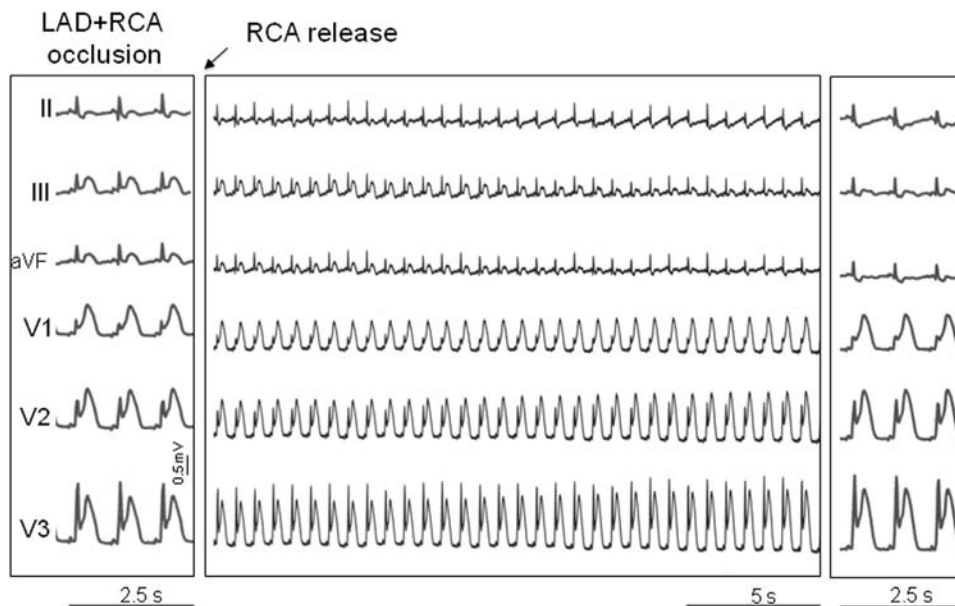


Figure 4 Effects of selective coronary reperfusion on the ischemic ECG changes induced by 5 minutes of double left anterior descending (LAD) and right coronary arteries (RCA) occlusion in an anesthetized pig. ECG leads II, III, aVF, and V₁–V₃ are shown at 5 minutes of double LAD and RCA occlusion (**left**) and during release of the RCA while the LAD remained occluded (**middle, right**). Release of the RCA induced fast normalization of ST-segment elevation in leads II and III with concurrent beat-to-beat ST-segment re-elevation in leads V₁–V₃. Time scale is indicated in seconds.

ST-segment re-elevation measured within the 30 seconds after reperfusion was approximately 50%. Two examples of the ST-segment behavior after selective release of the LAD or RCA in pigs with double occlusion are shown in Figures 3 and 4, respectively. In 2 of 7 pigs, we performed double LAD and RCA occlusion as the first intervention thereby not preceded by previous ischemia. In these cases, the trend of ST-segment changes induced by reperfusion of 1 of the 2 occluded vessels was comparable to that observed in the 5 pigs with previous ischemic episodes.

Isolated Langendorff perfused heart

Five complete isolated heart experiments were included in the analysis. In all hearts, the middle segments of the LAD and RCA were separately occluded for 5 minutes spaced by 10 minutes of reperfusion. Thereafter, a combined reocclusion of both vessels was performed.

As shown in Figure 5, mid-LAD occlusion induced significant ST-segment elevation in the epicardial, midmyocardial, and endocardial extracellular electrograms of the anterior LV region (maximal in endocardium: 3.0 ± 1.1 mV, $P = .003$) but failed to induce reciprocal ST-segment depression in lateral or posterior LV regions. Likewise, RCA occlusion induced transmural ST-segment elevation in the posterior LV region (maximal in endocardium: 3.0 ± 1.6 mV, $P = .03$) with no reciprocal ST-segment depression in the anterior or lateral areas. Simultaneous ligation of the LAD and RCA led to transmural elevation of the ST segment, maximal in the mid-myocardium of the anterior (2.3 ± 0.8 mV, $P = .002$) and posterior (2.1 ± 0.7 mV, $P = .003$) LV regions, respectively. The magnitude of ST-segment elevation was approximately 30% lower than that elicited by each previous single-vessel ligation. A typical

example of single and combined LAD and RCA occlusion is shown in Figure 5A. Selective release of 1 of the 2 occluded vessels did not induce appreciable re-elevation of the ST segment in the local recordings of the opposite ischemic zone. Moreover, no reciprocal ST-segment changes were observed during combined LAD and RCA ligation.

Discussion

ST-segment cancellation

Combined anterior and inferior regional ischemia was induced in the *in situ* and the isolated perfused pig hearts by occluding simultaneously the LAD and RCA. In comparison with a single myocardial ischemic location, simultaneous ischemia at these 2 opposite areas attenuated by approximately 60% the magnitude of ST-segment elevation in the ECG leads overlying the ischemic area and blunted the reciprocal ST-segment depression that was previously induced by a single LAD or RCA occlusion.

Two potential mechanisms may explain the attenuation of ST-segment changes during double coronary occlusion: (1) ischemic preconditioning elicited by the preceding single coronary occlusions^{8,9} or (2) true cancellation of the ST-segment potential secondary to the opposite location of the 2 ischemic regions. Our data support the concept that ST-segment cancellation rather than preconditioning was the prevailing mechanism. Indeed, selective reopening of 1 of the 2 simultaneously occluded coronary arteries was immediately followed by reversion of ST-segment elevation in the reperfused region and, at the same time, by concurrent beat-to-beat ST-segment re-elevation in leads overlying the opposite ischemic region. Moreover, a similar ST-segment behavior was observed in the 2 pigs submitted to double

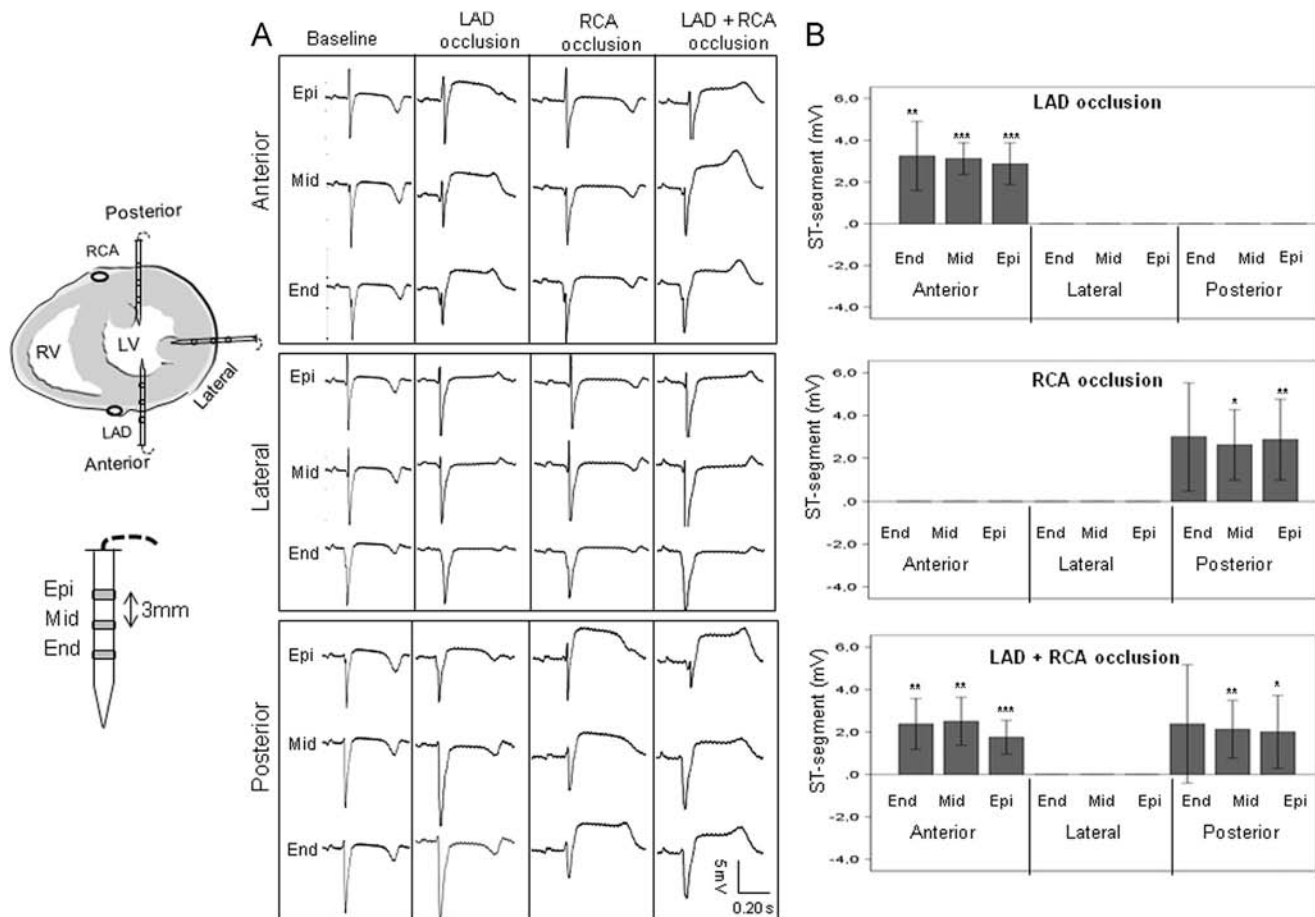


Figure 5 ST-segment changes in local extracellular electrograms induced by single and combined ligation of the left anterior descending (LAD) and right coronary arteries (RCA) in isolated Langendorff perfused pig heart. **A:** Epicardial (Epi), midmyocardial (Mid), and endocardial (End) electrograms recorded with needle electrodes inserted in the anterior, lateral, and posterior left ventricular wall at baseline and 5 minutes after single and combined LAD and RCA ligation in an isolated pig heart. **B:** ST-segment displacement (mean ± SD values [bars]) in local electrograms recorded in the anterior, lateral, and posterior ventricular regions in 5 isolated perfused pig hearts submitted to single and combined LAD and RCA occlusion separated by 10 minutes of reperfusion recovery. Coronary occlusion induced transmural regional ST-segment elevation without appreciable reciprocal ST-segment changes. Double coronary occlusion slightly attenuated ST-segment elevation. Asterisks indicate level of statistical significance (**P* < .05; ***P* < .01; ****P* < .001).

LAD and RCA occlusion as the first intervention and therefore free of ischemic preconditioning.

The mechanism of ST-segment cancellation induced by ischemia in opposite regions has not been directly elucidated but can be inferred from the solid angle theory.¹⁰ Indeed, the ST-segment potential (ϵ_{ST}) recorded by an exploring electrode is $\epsilon_{ST} = \Omega/4\pi(V_{mi} - V_{mN})K$, where Ω is the solid angle formed by lines from the recording electrode to every point along the ischemic boundary; V_{mi} and V_{mN} are the transmembrane potential at ischemic and normal regions, respectively; and K is a constant that corrects for differences in intracellular and extracellular conductivity and occupancy of heart muscle by interstitial tissue and space. The transmembrane potential differences existing between normal and ischemic (depolarized) myocardial cells drive local injury currents that flow across the ischemic border zone and are responsible for the elevation of the ST segment in local extracellular electrograms.^{11,12} When 2 ischemic myocardial areas are located in opposite sites, their corresponding solid angles are of opposite magnitude, and the resultant ST-segment magnitude may approach zero.^{10,13} In our study, the

degree of ST-segment cancellation induced by ischemia in opposite regions was of greater magnitude in precordial ECG leads than in local epicardial and intramural electrograms recorded in the ischemic regions. Hypothetically, this may indicate that the solid angle subtended at the precordium is more influenced by the summed solid angles generated at the boundaries of 2 ischemic regions than the solid angle subtended at sites in direct contact with ischemic myocardium.

An additional feature differentiating precordial and local electrograms was the lack of appreciable reciprocal ST-segment depression in the latter recordings. According to the mathematical predictions of the solid angle theory derived from epicardial and precordial recordings in anesthetized pigs with acute myocardial ischemia,¹⁴ a precordial electrode moving at a distance from the ischemic border zone will detect negative values and hence ST-segment depression. In contrast, an epicardial electrode closer to the heart will not detect negative values beyond the border zone.¹⁴ The injury currents cannot propagate at a distance of the ischemic zone because of their short space constant, and only sites close to

the border zone might disclose reciprocal ST-segment depression.¹¹ Moreover, a possible volume conductor effect on the reciprocal ST-segment changes in the isolated empty heart was excluded in a previous study in which we recorded simultaneously the conventional ECG leads and local intramural electrograms in anesthetized open chest pigs.¹⁵ In that study, acute occlusion of the RCA with a catheter balloon did not induce reciprocal ST-segment changes in local electrograms of the normal left anterior wall, but they were present in the precordial ECG leads projecting this particular normal region.¹⁵ Therefore, the reciprocal ST-segment depression observed in the 12-lead ECG likely is related to the conventional ECG lead system design and not the result of an active flow of injury currents propagating toward the distant normal myocardium.

During LAD occlusion, endocardial ST-segment elevation was greater than midmyocardial, and this was greater than epicardial. Whether this endo-epicardial gradient should lead to ST-segment depression rather than elevation in the overlying precordial surface ECG leads was elucidated in a previous study in anesthetized pigs in which a similar endo-epicardial gradient was always projected as ST-segment elevation in the simultaneously recorded precordial ECG leads.¹⁶

Clinical implications

Compelling evidence supporting extrapolation of the present findings to clinical electrocardiology is founded on the resemblance of the cellular electrophysiologic derangements induced by acute myocardial ischemia and the ECG patterns elicited by coronary occlusion at different locations in pigs^{12,15} and humans.^{12,17-19}

The ECG pattern induced by simultaneous LAD and RCA occlusion in our study (ST-segment elevation in leads III, aVF, aVR, V₁-V₅, and ST-segment depression in leads I, aVL, and V₆) was comparable to that described in patients with a similar double LAD and RCA occlusion.²⁻⁵ Likewise, ECG recordings in a clinical case report support the concept that ST-segment cancellation also occurs in humans with double coronary occlusion.⁵ In this particular patient,⁵ successful lysis of the thrombus in the LAD, while RCA occlusion persisted, allowed re-elevation of the ST segment in inferior leads (II, III, aVF) and appearance of reciprocal ST-segment depression in leads V₂-V₅ thus mimicking the ST-segment response elicited by selective reopening of 1 of the 2 occluded vessels in our pigs.

Patients with acute myocardial infarction caused by single occlusion of the distal LAD may also present with an ECG pattern of combined ST-segment elevation in inferior leads and in anterior leads.⁶ In these patients, elevation of the ST segment in inferior leads was thought to occur whenever the basal anterior LV wall was spared and the apical portion of the LV inferior wall was affected because the occluded LAD wrapped around the apex supplying this region.⁷ The differentiation between patients with single occlusion of the distal LAD and those with double LAD and RCA occlusion is of

clinical relevance because the latter group of patients had a worse prognosis. Although these patients may share a comparable ST-segment elevation pattern involving the precordial and inferior leads, we observed that double LAD and RCA occlusion elicited ST-segment depression in leads I and aVL in our pigs and also in clinical case reports of combined LAD and RCA occlusion.²⁻⁵ Important to make the distinction is the absence of ST-segment depression in leads I and aVL in patients with a single distal LAD occlusion.^{6,20}

Patients with multivessel coronary atherosclerotic disease can develop simultaneous ischemia at various myocardial regions under conditions of low cardiac output or increased myocardial oxygen demands; therefore, the resultant ischemic ST-segment changes could be cancelled. During exercise testing, this may lead to a falsely negative ECG response in patients with multivessel disease.¹

Study limitations

The patterns of ST-segment cancellation described in this study are valid for models of acute transmural myocardial ischemia and therefore might not apply when the combined ischemia in opposite regions is limited to the subendocardial layers. Although it is conceivable that combined subendocardial ischemia in opposite regions would also result into cancellation of ST-segment depression, this assumption has not yet been verified in experimental models of ongoing stable subendocardial ischemia.

During RCA occlusion, the magnitude of reciprocal ST depression in the precordial leads was greater than that of ST elevation in the inferior leads. This finding is in contrast with current clinical practice and likely could be explained by the fact that the pig heart is in close contact with the chest wall, and therefore the cardiac electrical potentials might be preferentially projected on the precordial than inferior ECG leads.

The time course of ischemic ST-segment changes in the *in situ* heart evolve more rapidly than in the isolated unloaded heart; therefore, the duration of ischemia in both models might not be fully comparable. However, after 5 minutes of coronary occlusion, the magnitude of ST-segment elevation in the local electrograms was remarkable (about 3 times greater than that recorded in the ECG leads), and this permitted assessment of ST-segment behavior after selective release of 1 occluded vessel in the isolated heart.

Conclusion

Simultaneous acute myocardial ischemia in opposite ventricular regions exerted a noticeable cancellation of both ST-segment elevation and reciprocal ST segment depression in the conventional 12-lead ECG. In contrast, this phenomenon was nearly absent in local transmural electrograms recorded directly in ischemic myocardial regions.

Acknowledgment

We thank Professor Hein J. Wellens for critical review of our manuscript.

References

- Madias JE, Khan M, Manyam B. The role of "ischemic ST-segment counterpoise" in rendering the response of exercise electrocardiogram falsely negative. *Clin Cardiol* 1997;20:489-492.
- Hosokawa S, Hiasa Y, Miyamoto H, Suzuki N, Takahashi T, Kishi K, Tanimoto M, Ohtani R. Acute myocardial infarction showing total occlusion of right coronary artery and thrombus formation of left anterior descending artery. *Jpn Heart J* 2001;42:365-369.
- Sia SK, Huang CN, Ueng KC, Wu YL, Chan KC. Double vessel acute myocardial infarction showing simultaneous total occlusion of left anterior descending artery and right coronary artery. *Circ J* 2008;72:1034-1036.
- Araszkievicz A, Olasinska-Wisniewska A, Skorupski W, Lesiak M, Mularek-Kubzdela T, Grajek S. Simultaneous occlusion of 2 coronary arteries-a rare cause of cardiogenic shock. *Am J Emerg Med* 2009;1175.e5-175.e7.
- Gan F, Hu D, Dai T. Acute multivessel coronary occlusion: a case report. *BMC Res Notes* 2012;5:523-527.
- Sadanandan S, Hochman JS, Kolodziej A, Criger DA, Ross A, Selvester R, Wagner GS. Clinical and angiographic characteristics of patients with combined anterior and inferior ST-segment elevation on the initial electrocardiogram during acute myocardial infarction. *Am Heart J* 2003;146:653-661.
- Sapin PM, Musselman DR, Dehmer GJ, Cascio WE. Implications of inferior ST-segment elevation accompanying anterior wall acute myocardial infarction for the angiographic morphology of the left anterior descending coronary artery morphology and site of occlusion. *Am J Cardiol* 1992;69:860-865.
- Deutsch E, Berger M, Kussmaul WG, Hirshfeld JW Jr, Herrmann HC, Laskey WK. Adaptation to ischemia during percutaneous transluminal coronary angioplasty: clinical, hemodynamic, and metabolic features. *Circulation* 1990;82:2044-2051.
- Cinca J, Wornor F, Carreno A, Coronel R, Soldevilla A, Perez-Villa F, Janse MJ, Soler-Soler J. T-Q S-T segment mapping and hyperemia in reperfused pig heart with ischemic preconditioning. *Am J Physiol* 1992;263:H1732-H1738.
- Holland RP, Brooks H. TQ-ST segment mapping: critical review and analysis of current concepts. *Am J Cardiol* 1977;40:110-129.
- Janse MJ, Cinca J, Moréna H, Fiolet JW, Kléber AG, de Vries GP, Becker AE, Durrer D. The "border zone" in myocardial ischemia: an electrophysiological, metabolic, and histochemical correlation the pig heart. *Circ Res* 1979;44:576-588.
- Cinca J, Janse MJ, Moréna H, Candell J, Valle V, Durrer D. Mechanism and time course of the early electrical changes during acute coronary artery occlusion: an attempt to correlate the early ECG changes in man to the cellular electrophysiology in the pig. *Chest* 1980;77:499-505.
- Fozzard HA, DasGupta DS. ST-segment potentials and mapping: theory and experiments. *Circulation* 1976;54:533-537.
- Holland RP, Brooks H, Lidl B. Spatial and nonspatial influences on TQ-ST segment deflection of ischemia: theoretical and experimental analysis in the pig. *J Clin Invest* 1977;60:197-214.
- Noriega FJ, Jorge E, Arzamendi D, Cinca J. Mechanism and diagnostic potential of reciprocal ECG changes induced by acute coronary artery occlusion in pigs. *Heart Rhythm* 2013;10:883-890.
- Cinca J, Figueras J, Bardají A, Rius J. Retraso del ECG convencional en reflejar las alteraciones eléctricas del área isquémica en el cerdo. *Rev Esp Cardiol* 1986;39:47-52.
- Camara EJ, Chandra N, Ouyang P, Gottlieb SH, Shapiro EP. Reciprocal ST change in acute myocardial infarction: assessment by electrocardiography and echocardiography. *J Am Coll Cardiol* 1983;2:251-257.
- Rude RE, Croft CH, Willerson JT. "Reciprocal" anterior ST depression early in the course of transmural inferior myocardial infarction: an ECG finding of uncertain clinical significance. *Int J Cardiol* 1983;4:80-85.
- Becker RC, Alpert JS. Electrocardiographic ST segment depression in coronary heart disease. *Am Heart J* 1988;115:862-868.
- Engelen DJ, Gorgels AP, Cheriex EC, De Muinck ED, Ophuis AJ, Dassen WR, Vainer J, Van Ommen VG, Wellens HJ. Value of the electrocardiogram in localizing the occlusion site in the left anterior descending coronary artery in acute anterior myocardial infarction. *J Am Coll Cardiol* 1999;34:389-395.

CLINICAL PERSPECTIVES

Using an experimental model close to human cardiac electrophysiology, we disclosed the cancelling effect elicited by extensive myocardial ischemia on ECG ST-segment patterns. Compared with 1-site ischemia induced by single LAD or RCA occlusion, extensive ischemia induced by simultaneous LAD and RCA occlusion depicted less ST-segment elevation and absence of reciprocal ST-segment changes. Thus, the ECG patterns currently used to identify the occluded coronary artery will not be fully applicable if ischemia developed simultaneously in 2 opposite myocardial regions.

In clinical practice, ischemia in opposite myocardial regions may develop in patients with multivessel coronary atherosclerotic disease during increased myocardial oxygen demands (ie, exercise testing) or in those presenting with simultaneous occlusion of 2 coronary vessels, but the resultant ECG patterns have not been well characterized. Our observations may help improve the ECG diagnosis of transmural myocardial ischemia in opposite cardiac regions in patients with acute coronary syndromes. However, in patients with diffuse ischemia limited to the subendocardial regions, the cancelling effect on ECG changes would need to be confirmed using purposely designed models of stable acute subendocardial ischemia.

Our findings in the isolated heart further indicated that the cancelling effect on ST-segment behavior is more apparent in peripheral ECG leads than in local extracellular electrograms.

DISCUSIÓN

Este trabajo aporta información traslacional original sobre el mecanismo electrofisiológico e implicaciones clínicas de las alteraciones del segmento ST y del complejo QRS en el curso del infarto agudo de miocardio producido por oclusión arterial coronaria. La parte experimental se ha realizado en un modelo porcino de corazón in situ y corazón aislado perfundido por la técnica de Langendorff. La parte clínica se ha realizado en una cohorte de pacientes con infarto agudo de miocardio sometidos a angioplastia primaria, en quienes se dispone de información fehaciente de la localización de la oclusión arterial coronaria.

1. Génesis y comportamiento de los cambios recíprocos del segmento ST y del complejo QRS

El Artículo 1 (Noriega FJ et al, Heart Rhythm 2013) muestra que en un modelo porcino de isquemia miocárdica aguda producida por una oclusión arterial coronaria única, es decir, sin isquemia subendocárdica asociada, se observa depresión recíproca del segmento ST y crecimiento de la onda S en las derivaciones del ECG no enfrentadas al área isquémica, mientras que esos cambios se encuentran ausentes en los electrogramas locales registrados directamente en las regiones miocárdicas no isquémicas.

Dos han sido los mecanismos que clásicamente se han empleado para explicar la aparición de los cambios recíprocos del segmento ST en el transcurso de un infarto: proyección a distancia de los cambios directos del segmento ST generados en el área isquémica (20-26), o verdadera alteración del segmento ST debida a la presencia de isquemia subendocárdica añadida a distancia (27-29). Las características del modelo, basadas en la oclusión coronaria única, con ausencia de enfermedad aterosclerótica en el resto de arterias corroborada por coronariografía, permiten descartar la isquemia subendocárdica añadida, lo que impide que ésta sea, por tanto, un mecanismo generador de los cambios recíprocos.

Las corrientes de lesión generadas por la diferencia de potencial de membrana entre las células del área isquémica y las del área no isquémica son las responsables de la elevación del segmento ST en las derivaciones del ECG enfrentadas al área isquémica (18-19). El hecho de registrar depresión del segmento ST en las derivaciones alejadas del área isquémica en el ECG convencional, pero su ausencia en los electrogramas locales correspondientes a las mismas regiones no isquémicas, demuestra que no hay una verdadera propagación de la corriente de lesión desde la zona isquémica hasta las regiones distantes de miocardio no isquémico, sino que su presencia se debe a las características del sistema de registro del ECG convencional, en concordancia con la teoría de ángulo sólido (16, 37).

La isquemia miocárdica aguda reduce la velocidad de propagación del frente de activación local, lo que genera un crecimiento de la onda R y un ensanchamiento del QRS en los electrogramas locales (19). El crecimiento de la onda S observado en nuestro estudio en las derivaciones del ECG alejadas del área isquémica podría ser considerado como una proyección recíproca del crecimiento de la onda R generado en el área isquémica. La ausencia de dicho crecimiento recíproco de la onda S en los electrogramas locales situados en las regiones no isquémicas, al igual que ocurría con los cambios recíprocos del segmento ST, se explica también por la teoría del ángulo sólido (16, 37).

2. Correlación entre los patrones del segmento ST y la angiografía coronaria

Las alteraciones del ECG registradas durante la isquemia miocárdica aguda fueron por primera vez mencionadas en 1920 (38). Desde entonces, múltiples estudios, tanto clínicos (31-36, 39-43) como experimentales (18-19, 44-48), han descrito exhaustivamente los cambios electrocardiográficos acaecidos durante un infarto agudo de miocardio, estableciendo una correlación eléctrica y anatómica. Se describen así unos patrones electrocardiográficos específicos que permiten realizar una aproximación de la localización de la oclusión arterial coronaria responsable de la isquemia miocárdica (31-36).

El Artículo 2 (Noriega FJ et al, Am J Cardiol 2014), en el que se analizan los ECG de 289 pacientes afectados de un infarto agudo de miocardio, muestra los

diversos patrones electrocardiográficos combinados de ascensos y descensos del segmento ST en función de la localización de la oclusión arterial coronaria. Dichos patrones están en concordancia con los registros realizados en el modelo experimental de isquemia miocárdica, descritos en el Artículo 1.

La presencia de cambios recíprocos en las derivaciones inferiores en el transcurso de un infarto anterior solo se ve en los pacientes que presentan oclusión de la arteria descendente anterior a nivel proximal, con mayor extensión del infarto, y no en los que presentan oclusión de la arteria descendente anterior a nivel medio o distal (31-34). Dichos hallazgos se encuentran presentes tanto en nuestro modelo experimental como en el registro clínico.

La oclusiones de las arterias coronaria derecha o circunfleja muestran un patrón electrocardiográfico similar tanto en oclusiones proximales como medio-distales, consistente en elevación del segmento ST en derivaciones inferiores y descenso recíproco del segmento ST en aVL y V2. Diversos criterios se han descrito para diferenciar los patrones electrocardiográficos de oclusión de coronaria derecha y de circunfleja (35-36). Nuestros datos recogen, adicionalmente, la elevación del segmento ST en la derivación V6 como otro posible criterio sugestivo de oclusión de circunfleja, aunque dicho hallazgo deberá ser corroborado con estudios que incluyan un mayor número de pacientes.

3. Comportamiento del segmento ST en la enfermedad coronaria multivaso

Los diversos patrones electrocardiográficos descritos en el transcurso de un infarto agudo de miocardio, y su correlación angiográfica, se basan en estudios realizados a partir de oclusiones coronarias únicas (31-36). No obstante, dichos patrones no han sido validados en pacientes con enfermedad arterial coronaria múltiple, pudiendo verse afectados por la potencial presencia de isquemia miocárdica simultánea en varios territorios.

El Artículo 2 (Noriega FJ et al, Am J Cardiol 2014) establece que los patrones electrocardiográficos que identifican la arteria coronaria responsable son válidos en presencia de enfermedad multivaso, presentando solamente sutiles diferencias en algunas derivaciones concretas. Estas diferencias consisten básicamente en una mayor expansión de los cambios recíprocos en los casos de enfermedad multivaso.

En el infarto anterior por oclusión de la arteria descendente anterior proximal, la presencia de enfermedad multivaso aumenta la magnitud de los cambios recíprocos en derivaciones inferiores, en los casos en los que se encuentra ocluida la primera rama septal. En el infarto inferior, los cambios recíprocos que afectan a las derivaciones V2-V3 en las oclusiones de la arteria coronaria derecha o de la arteria circunfleja, se extienden hasta la derivación V4 en presencia de enfermedad multivaso.

Aunque no podemos establecer el mecanismo de estas diferencias, los pacientes con enfermedad multivaso podrían desarrollar adicionalmente isquemia subendocárdica a distancia, pudiendo observarse una magnificación de los cambios recíprocos del segmento ST (49).

4. Isquemia miocárdica simultánea en dos regiones opuestas

El artículo 3 (Cinca J et al, Heart Rhythm 2014) muestra que en un modelo porcino de isquemia miocárdica aguda en dos territorios opuestos, producida por oclusión simultánea de dos arterias coronarias, se observa una cancelación de las alteraciones del segmento ST, tanto directas como recíprocas, registradas en el ECG de superficie. Sin embargo, dicha cancelación es prácticamente inapreciable en los electrogramas locales registrados directamente en las regiones miocárdicas isquémicas.

Dos mecanismos potenciales podrían explicar la atenuación de los cambios del segmento ST durante la isquemia miocárdica simultánea: preconditionamiento producido por periodos previos de isquemia en uno o ambos territorios isquémicos (50-51), o verdadera cancelación del potencial eléctrico debida a la localización opuesta de las dos regiones isquémicas.

El diseño de nuestro modelo, que nos permitía realizar un registro continuo del ECG durante las oclusiones coronarias y también durante las aperturas

arteriales, muestra como durante la oclusión arterial simultánea, tras la apertura selectiva de una de las dos arterias, se produce en escasos segundos una reversión de la elevación del segmento ST en las derivaciones correspondientes al área reperfundida, junto con la desaparición inmediata de la cancelación eléctrica en las derivaciones correspondientes al área que persiste isquémica. Tales hallazgos sugieren que dichas modificaciones se deban a una verdadera cancelación eléctrica, mientras que si fuera el preconditionamiento isquémico el responsable, no se observaría recuperación de la cancelación tras la apertura de una de las arterias coronarias de forma tan inmediata.

Aunque la teoría del ángulo sólido no ha sido empleada para describir la cancelación eléctrica producida por dos áreas isquémicas simultáneas, puede inferirse de ésta que los ángulos sólidos creados desde un electrodo explorador sobre dos áreas isquémicas enfrentadas presentarán magnitudes opuestas, acercándose la magnitud resultante a cero (16, 52).

CONCLUSIONES

- Las alteraciones recíprocas del segmento ST y del complejo QRS producidas por oclusión arterial coronaria aguda se encuentran presentes sin necesidad de que exista isquemia subendocárdica añadida a distancia, y se deben a las características del sistema de registro del ECG.
- Las alteraciones recíprocas del segmento ST permiten, cuando se integran a las alteraciones directas, realizar una aproximación más precisa de la localización de la oclusión arterial coronaria.
- La presencia de cambios recíprocos en derivaciones inferiores en el transcurso de un infarto anterior es indicativa de isquemia extensa debida a oclusión coronaria de la arteria descendente anterior a nivel proximal.
- Los patrones electrocardiográficos de alteraciones del segmento ST producidos por oclusión arterial coronaria no se ven esencialmente modificados en presencia de enfermedad multivaso.
- La isquemia miocárdica simultánea en dos regiones ventriculares opuestas, producida por oclusión de dos arterias coronarias, genera una cancelación de los cambios directos y recíprocos del segmento ST en el ECG convencional.

BIBLIOGRAFÍA

1. Go AS, Mozaffarian D, Roger VL, Benjamin EJ, Berry JD, Blaha MJ, Dai S, Ford ES, Fox CS, Franco S, Fullerton HJ, Gillespie C, Hailpern SM, Heit JA, Howard VJ, Huffman MD, Judd SE, Kissela BM, Kittner SJ, Lackland DT, Lichtman JH, Lisabeth LD, Mackey RH, Magid DJ, Marcus GM, Marelli A, Matchar DB, McGuire DK, Mohler ER 3rd, Moy CS, Mussolino ME, Neumar RW, Nichol G, Pandey DK, Paynter NP, Reeves MJ, Sorlie PD, Stein J, Towfighi A, Turan TN, Virani SS, Wong ND, Wood D, Turner MB; American Heart Association Statistics Committee and Stroke Statistics Subcommittee. Heart disease and stroke statistics--2014 update: a report from the American Heart Association. *Circulation* 2014;129:e28-e292.
2. Nichols M, Townsend N, Scarborough P, Rayner M. Cardiovascular disease in Europe 2014: epidemiological update. *Eur Heart J* 2014;35:2950-2959.
3. World Health Organization. Media Centre. Geneva: WHO; 2014. Disponible en: www.who.int/mediacentre/en/
4. Instituto Nacional de Estadística. Operaciones estadísticas: Salud. Madrid: INE; 2014. Disponible en : www.ine.es/inebmenu/mnu_salud.htm
5. Banegas JR, Villar F, Graciani A, Rodríguez-Artalejo F. Epidemiología de las enfermedades cardiovasculares en España. *Rev Esp Cardiol* 2006;6:3-12.

6. Klocke FJ. Measurements of coronary blood flow and degree of stenosis: current clinical implications and continuing uncertainties. *J Am Coll Cardiol* 1983;1:31-41.
7. Kloner RA, Jennings RB. Consequences of brief ischemia: Stunning, preconditioning, and their clinical implications: Part 1. *Circulation* 2001;104:2981-2989.
8. Shaw RM, Rudy Y. Electrophysiologic effects of acute myocardial ischemia: a theoretical study of altered cell excitability and action potential duration. *Cardiovasc Res* 1997;35:256-272.
9. Janse MJ, Kléber AG. Electrophysiological changes and ventricular arrhythmias in the early phase of regional myocardial ischemia. *Circ Res* 1981;49:1069-1081.
10. Gima K, Rudy Y. Ionic current basis of electrocardiographic waveforms: a model study. *Circ Res* 2002;90:889-896.
11. Montalescot G, Sechtem U, Achenbach S, Andreotti F, Arden C, Budaj A, Bugiardini R, Crea F, Cuisset T, Di Mario C, Ferreira JR, Gersh BJ, Gitt AK, Hulot JS, Marx N, Opie LH, Pfisterer M, Prescott E, Ruschitzka F, Sabaté M, Senior R, Taggart DP, van der Wall EE, Vrints CJ. 2013 ESC guidelines on the management of stable coronary artery disease: the task force on the management of the stable coronary artery disease of the European Society of Cardiology. *Eur Heart J* 2013;34:2949-3003.
12. Kher N, Marsh JD. Pathobiology of atherosclerosis—a brief review. *Semin Thromb Hemost* 2004;30:665-672.

13. Cannon CP, Braunwald E. Angina inestable e infarto de miocardio sin elevación del ST. En: Libby P, Bonow RO, Mann DL, Zipes DP, Braunwald E, editores. Braunwald: Tratado de cardiología. Texto de medicina cardiovascular. 8ª ed. Barcelona: Elsevier; 2009. p.1319-1351.
14. Bayes de Luna A. Electrocardiografía clínica. 7ª ed. Barcelona: Publicaciones Permanyer; 2012.
15. Mirvis DM, Goldberger AL. Electrocardiografía. En: Libby P, Bonow RO, Mann DL, Zipes DP, Braunwald E, editores. Braunwald: Tratado de cardiología. Texto de medicina cardiovascular. 8ª ed. Barcelona: Elsevier; 2009. p. 149-193.
16. Holland RP, Brooks H, Lidl B. Spatial and nonspatial influences on the TQ-ST segment deflection of ischemia: theoretical and experimental analysis in the pig. J Clin Invest 1977;60:197-214.
17. Kligfield P, Gettes LS, Bailey JJ, Childers R, Deal BJ, Hancock EW, van Herpen G, Kors JA, Macfarlane P, Mirvis DM, Pahlm O, Rautaharju P, Wagner GS, Josephson M, Mason JW, Okin P, Surawicz B, Wellens H. Recommendations for the standardization and interpretation of the electrocardiogram: part I: the electrocardiogram and its technology a scientific statement from the American Heart Association Electrocardiography and Arrhythmias Committee, Council on Clinical Cardiology; the American College of Cardiology Foundation; and the Heart Rhythm Society endorsed by the International Society for Computerized Electrocardiology. J Am Coll Cardiol 2007;49:1109-1127.

18. Kléber AG, Janse MJ, van Capelle FJ, Durrer D. Mechanism and time course of S-T and T-Q segment changes during acute regional myocardial ischemia in the pig heart determined by extracellular and intracellular recordings. *Circ Res* 1978;42:603-613.
19. Cinca J, Janse MJ, Moréna H, Candell J, Valle V, Durrer D. Mechanism and time course of the early electrical changes during acute coronary artery occlusion. An attempt to correlate the early ECG changes in man to the cellular electrophysiology in the pig. *Chest* 1980;77:499-505.
20. Mirvis DM. Physiologic bases for anterior ST segment depression in patients with acute inferior wall myocardial infarction. *Am Heart J* 1988;116:1308-1322.
21. Becker RC, Alpert JS. Electrocardiographic ST segment depression in coronary heart disease. *Am Heart J* 1988;115:862-868.
22. Little WC, Rogers EW, Sodums MT. Mechanism of anterior ST segment depression during acute inferior myocardial infarction. Observations during coronary thrombolysis. *Ann Intern Med* 1984;100:226-229.
23. Quyyumi AA, Crake T, Rubens MB, Levy RD, Rickards AF, Fox KM. Importance of "reciprocal" electrocardiographic changes during occlusion of left anterior descending coronary artery. Studies during percutaneous transluminal coronary angioplasty. *Lancet* 1986;327:347-350.
24. Tabbalat RA, Haft JI. Are reciprocal changes a consequence of "ischemia at a distance" or merely a benign electric phenomenon? A PTCA study. *Am Heart J* 1993;126:95-103.

25. Celik S, Yilmaz R, Baykan M, Orem C, Erdöl C. Are reciprocal changes a consequence of "ischemia at a distance" or merely a benign electrical phenomenon? A pulsed-wave tissue Doppler echocardiographic study. *Ann Noninvasive Electrocardiol* 2003;8:302-307.
26. Rude RE, Croft CH, Willerson JT. "Reciprocal" anterior ST depression early in the course of transmural inferior myocardial infarction: an ECG finding of uncertain clinical significance. *Int J Cardiol* 1983;4:80-85.
27. Zoghi M, Gürgün C, Yavuzgil O, Türkoglu I, Kültürsay H, Akilli A, Akin M, Türkoglu C. The angiographic correlation between ST segment depression in noninfarcted leads and the extent of coronary artery disease in patients with acute inferior myocardial infarction: a clue for multivessel disease. *Can J Cardiol* 2003;19:67-71.
28. Forfar JC. Reciprocal ST segment changes in acute myocardial infarction: informative or incidental? *Q J Med* 1989;72:763-765.
29. Gibelin P, Gilles B, Baudouy M, Guarino L, Morand P. Significance of ST segment depression in the precordial leads during the acute phase of inferior myocardial infarction. *Arch Mal Coeur Vaiss* 1985;78:1453-1461.
30. Wagner GS, Macfarlane P, Wellens H, Josephson M, Gorgels A, Mirvis DM, Pahlm O, Surawicz B, Kligfield P, Childers R, Gettes LS, Bailey JJ, Deal BJ, Gorgels A, Hancock EW, Kors JA, Mason JW, Okin P, Rautaharju PM, van Herpen G. AHA/ACCF/HRS recommendations for the standardization and interpretation of the electrocardiogram: part VI: acute ischemia/infarction: a scientific statement from the American Heart Association Electrocardiography and Arrhythmias Committee, Council on

- Clinical Cardiology; the American College of Cardiology Foundation; and the Heart Rhythm Society. Endorsed by the International Society for Computerized Electrocardiology. *J Am Coll Cardiol* 2009;53:1003-1011.
31. Engelen DJ, Gorgels AP, Cheriex EC, De Muinck ED, Ophuis AJ, Dassen WR, Vainer J, van Ommen VG, Wellens HJ. Value of the electrocardiogram in localizing the occlusion site in the left anterior descending coronary artery in acute anterior myocardial infarction. *J Am Coll Cardiol* 1999;34:389-395.
32. Fiol M, Carrillo A, Cygankiewicz I, Velasco J, Riera M, Bayés-Genis A, Gómez A, Peral V, Bethencourt A, Goldwasser D, Molina F, Bayés de Luna A. A new electrocardiographic algorithm to locate the occlusion in left anterior descending coronary artery. *Clin Cardiol* 2009;32:E1-E6.
33. Tamura A, Kataoka H, Mikuriya I, Nasu M. Inferior ST segment depression as a useful marker for identifying proximal left anterior descending artery occlusion during acute anterior myocardial infarction. *Eur Heart J* 1995;16:1795-1799.
34. Birnbaum Y, Solodky A, Herz I, Kusniec J, Rechavia E, Sulkes J, Sclarovsky S. Implications of inferior ST-segment depression in acute anterior myocardial infarction: electrocardiographic and angiographic correlation. *Am Heart J* 1994;127:1467-1473.
35. Kosuge M, Kimura K, Ishikawa T, Hongo Y, Mochida Y, Sugiyama M, Tochikubo O. New electrocardiographic criteria for predicting the site of coronary artery occlusion in inferior wall acute myocardial infarction. *Am J Cardiol* 1998;82:1318-1322.

36. Fiol M, Cygankiewicz I, Carrillo A, Bayés-Genis A, Santoyo O, Gómez A, Bethencourt A, Bayés de Luna A. Value of electrocardiographic algorithm based on “ups and downs” of ST in assessment of a culprit artery in evolving inferior wall acute myocardial infarction. *Am J Cardiol* 2004;94:709-714.
37. Holland RP, Arnsdorf MF. Solid angle theory and the electrocardiogram: physiologic and quantitative interpretations. *Prog Cardiovasc Dis* 1977;19:431-457.
38. Pardee HE. An electrocardiographic sign of coronary artery obstruction. *Arch Intern Med* 1920;26:244.
39. Camara EJ, Chandra N, Ouyang P, Gottlieb SH, Shapiro EP. Reciprocal ST change in acute myocardial infarction: assessment by electrocardiography and echocardiography. *J Am Coll Cardiol* 1983;2:251-257.
40. Huey BL, Beller GA, Kaiser DL, Gibson RS. A comprehensive analysis of myocardial infarction due to left circumflex artery occlusion: comparison with infarction due to right coronary artery and left anterior descending artery occlusion. *J Am Coll Cardiol* 1988;12:1156-1166.
41. Surawicz B. Reversible QRS changes during acute myocardial ischemia. *J Electrocardiol* 1998;31:209-220.
42. Birnbaum Y, Sclarovsky S, Solodky A, Tschori J, Herz I, Sulkes J, Mager A, Rechavia E. Prediction of the level of left anterior descending coronary artery obstruction during anterior wall acute myocardial infarction by the admission electrocardiogram. *Am J Cardiol* 1993;72:823-826.

43. Sasaki K, Yotsukura M, Sakata K, Yoshino H, Ishikawa K. Relation of ST-segment changes in inferior leads during anterior wall acute myocardial infarction to length and occlusion site of the left anterior descending coronary artery. *Am J Cardiol* 2001;87:1340-1345.
44. Wolferth CC, Bellet S, Livezey MM, Murphy FD. Negative displacement of the RS-T segment in the electrocardiogram and its relationships to positive displacement: an experimental study. *Am Heart J* 1945;29:220-245.
45. Alzamora-Castro V, Battilana G, Abugattas R. The electrical manifestations observed in damaged or injured cardiac muscle. An experimental study. *Am Heart J* 1957;54:254-263.
46. Janse MJ, Cinca J, Moréna H, Fiolet JW, Kléber AG, de Vries GP, Becker AE, Durrer D. The "border zone" in myocardial ischemia. An electrophysiological, metabolic, and histochemical correlation in the pig heart. *Circ Res* 1979;44:576-588.
47. Franz MR, Flaherty JT, Platia EV, Bulkley BH, Weisfeldt ML. Localization of regional myocardial ischemia by recording of monophasic action potentials. *Circulation* 1984;69:593-604.
48. Wiegerinck RF, Gálvez-Monton C, Jorge E, Martínez R, Ricart E, Cinca J. Changes in QRS duration and R-wave amplitude in electrocardiogram leads with ST segment elevation differentiate epicardial and transmural myocardial injury. *Heart Rhythm* 2010;7:1667-1673.
49. Kyriakidis M, Antonopoulos A, Barbetseas J, Aspiotis N, Georgiakodis F, Sfrikakis P, Toutouzas P. Correlation of reciprocal ST-segment

- depression after acute myocardial infarction with coronary angiographic findings. *Int J Cardiol* 1992;36:163-168.
50. Deutsch E, Berger M, Kussmaul WG, Hirshfeld JW Jr, Herrmann HC, Laskey WK. Adaptation to ischemia during percutaneous transluminal coronary angioplasty. Clinical, hemodynamic, and metabolic features. *Circulation* 1990;82:2044-2051.
51. Cinca J, Worner F, Carreno A, Coronel R, Soldevilla A, Perez-Villa F, Janse MJ, Soler-Soler J. T-Q, S-T segment mapping and hyperemia in reperfused pig heart with ischemic preconditioning. *Am J Physiol* 1992;263:H1732-H1738.
52. Fozzard HA, DasGupta DS. ST-segment potentials and mapping. Theory and experiments. *Circulation* 1976;54:533-537.